

# Anatomical Images

provided by Anatomical Chart Company

**STEDMAN'S**  
Electronic Medical

Dictionary  
VERSION 6.0



**View Thumbnail Images**



**View Image Titles**

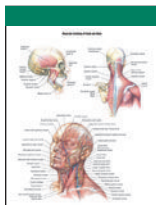


**How to Navigate**

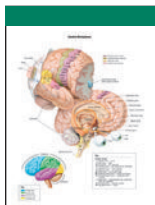
Images © Anatomical Chart Company  
[www.anatomical.com](http://www.anatomical.com)

# Gallery of Images

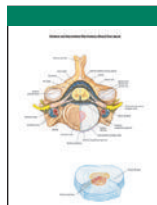
Click on thumbnail to view image



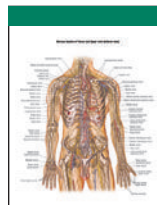
MUSCULAR ANATOMY OF HEAD AND NECK



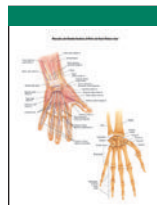
CEREBRAL HEMISPHERES



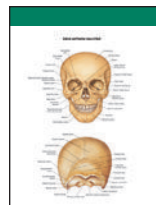
VERTEBRAL AND INTERVERTEBRAL DISK ANATOMY



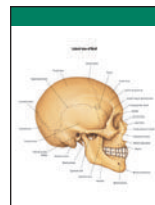
NERVOUS SYSTEM OF THORAX AND UPPER LIMB (ANTERIOR VIEW)



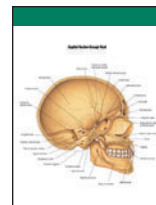
MUSCULAR AND SKELETAL ANATOMY OF WRIST AND HAND (PALMAR VIEW)



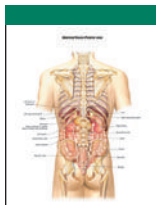ANTERIOR AND POSTERIOR VIEWS OF SKULL



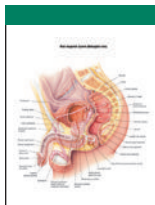
LATERAL VIEW OF SKULL



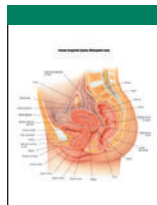
SAGITTAL SECTION THROUGH SKULL



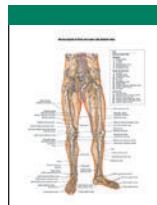
ABDOMINAL VISCERA (POSTERIOR VIEW)



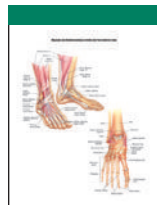
MALE UROGENITAL SYSTEM (MIDSAGITTAL VIEW)



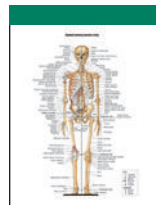FEMALE UROGENITAL SYSTEM (MIDSAGITTAL VIEW)



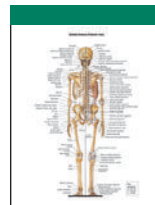
NERVOUS SYSTEM OF PELVIS AND LOWER LIMB (ANTERIOR VIEW)



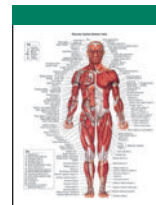
MUSCULAR AND SKELETAL ANATOMY OF ANKLE AND FOOT (ANTERIOR VIEW)



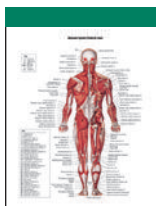VISCERA OF THORAX (ANTERIOR VIEW)



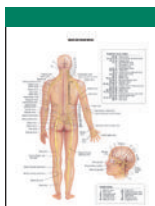
ANATOMY OF THE HEART (ANTERIOR VIEW)



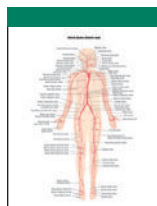ABDOMINAL VISCERA (ANTERIOR VIEW)



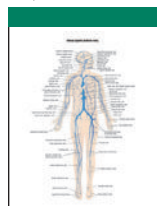
MUSCULAR SYSTEM (POSTERIOR VIEW)



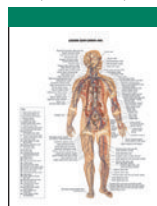SPINAL AND CRANIAL NERVES



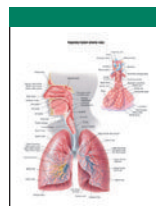
ARTERIAL SYSTEM (ANTERIOR VIEW)



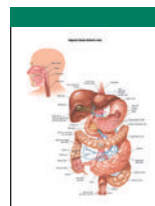
VENOUS SYSTEM (ANTERIOR VIEW)



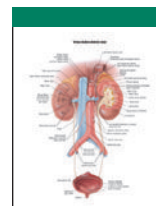
LYMPHATIC SYSTEM (ANTERIOR VIEW)



RESPIRATORY SYSTEM (ANTERIOR VIEW)



DIGESTIVE SYSTEM (ANTERIOR VIEW)



URINARY SYSTEM (ANTERIOR VIEW)

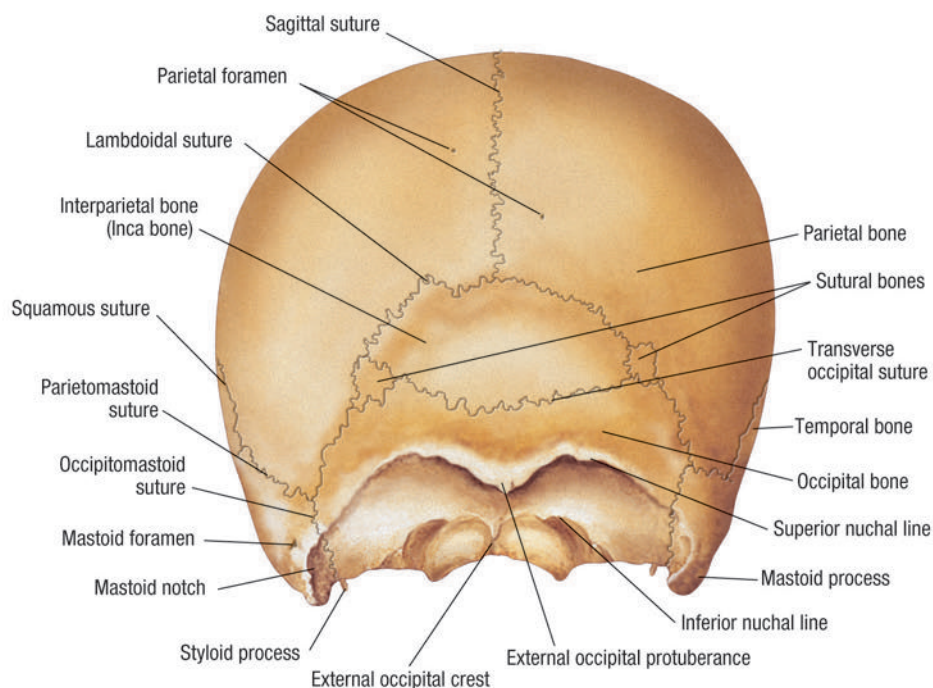
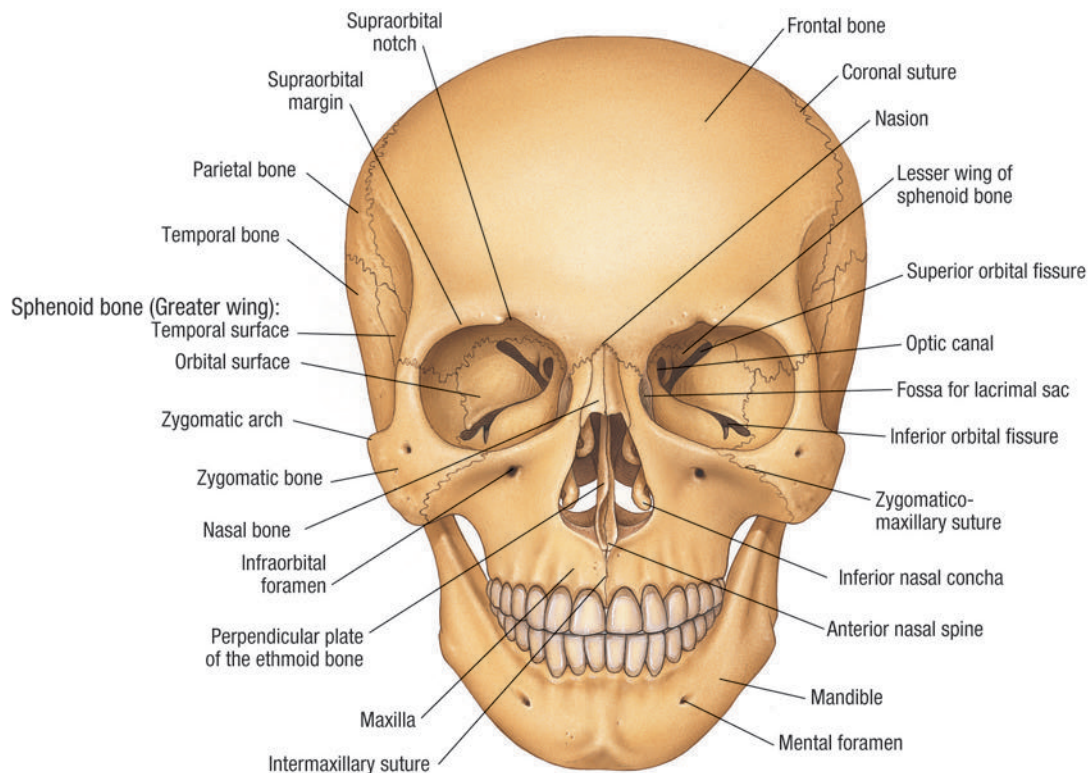
# List of Images

Click on image  
title to view image

1. ANTERIOR AND POSTERIOR VIEWS OF SKULL
2. LATERAL VIEW OF SKULL
3. SAGITTAL SECTION THROUGH SKULL
4. MUSCULAR ANATOMY OF HEAD AND NECK
5. CEREBRAL HEMISPHERES
6. VERTEBRAL AND INTERVERTEBRAL DISK ANATOMY
7. NERVOUS SYSTEM OF THORAX AND UPPER LIMB (ANTERIOR VIEW)
8. MUSCULAR AND SKELETAL ANATOMY OF WRIST AND HAND (PALMAR VIEW)
9. VISCERA OF THORAX (ANTERIOR VIEW)
10. ANATOMY OF THE HEART (ANTERIOR VIEW)
11. ABDOMINAL VISCERA (ANTERIOR VIEW)
12. ABDOMINAL VISCERA (POSTERIOR VIEW)
13. MALE UROGENITAL SYSTEM (MIDSAGITTAL VIEW)
14. FEMALE UROGENITAL SYSTEM (MIDSAGITTAL VIEW)
15. NERVOUS SYSTEM OF PELVIS AND LOWER LIMB (ANTERIOR VIEW)
16. MUSCULAR AND SKELETAL ANATOMY OF ANKLE AND FOOT (ANTERIOR VIEW)
17. SKELETAL ANATOMY (ANTERIOR VIEW)
18. SKELETAL ANATOMY (POSTERIOR VIEW)
19. MUSCULAR SYSTEM (ANTERIOR VIEW)
20. MUSCULAR SYSTEM (POSTERIOR VIEW)
21. SPINAL AND CRANIAL NERVES
22. ARTERIAL SYSTEM (ANTERIOR VIEW)
23. VENOUS SYSTEM (ANTERIOR VIEW)
24. LYMPHATIC SYSTEM (ANTERIOR VIEW)
25. RESPIRATORY SYSTEM (ANTERIOR VIEW)
26. DIGESTIVE SYSTEM (ANTERIOR VIEW)
27. URINARY SYSTEM (ANTERIOR VIEW)

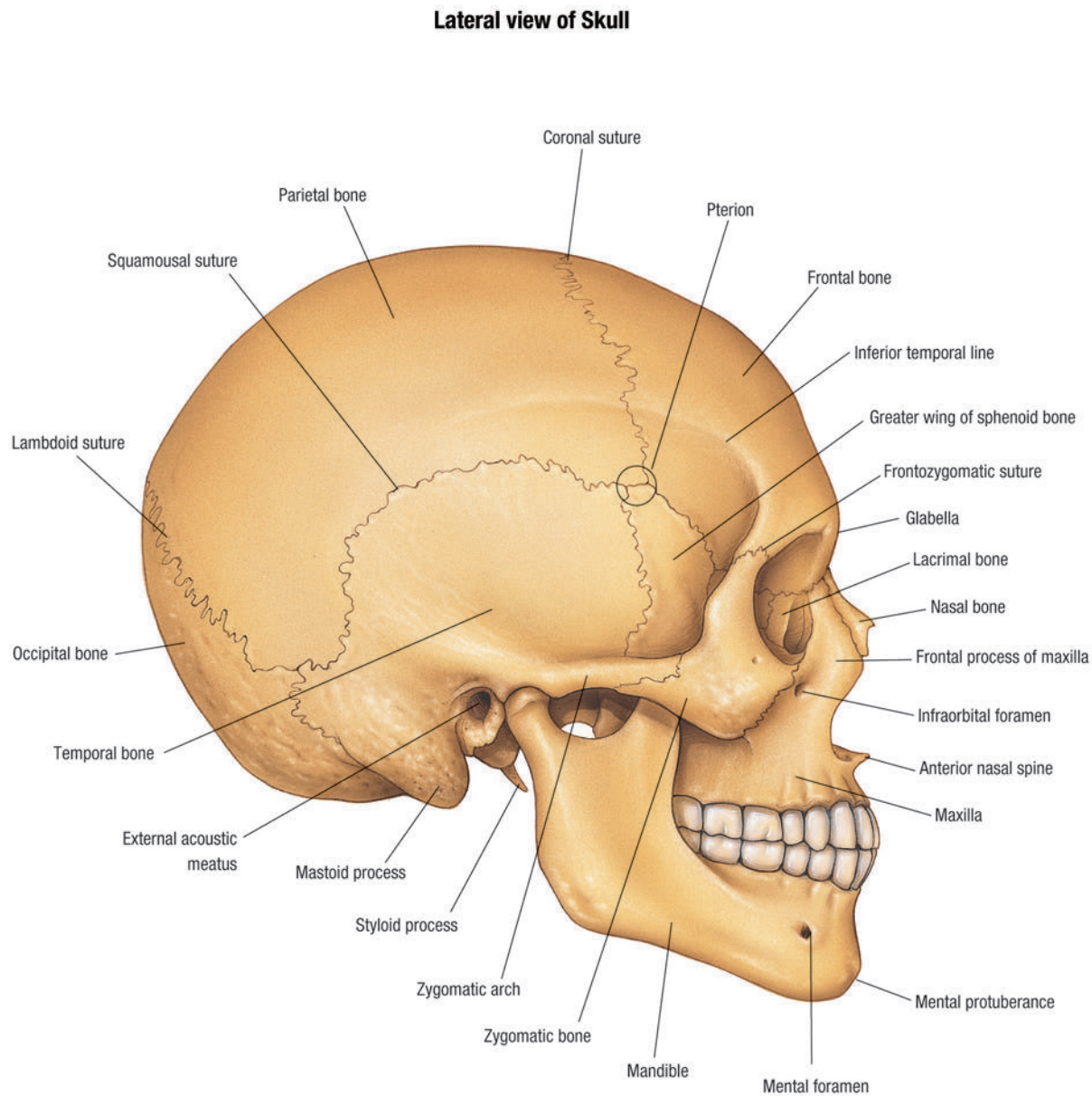
# PLATE 1: ANTERIOR AND POSTERIOR VIEWS OF SKULL

**Anterior and Posterior views of Skull**



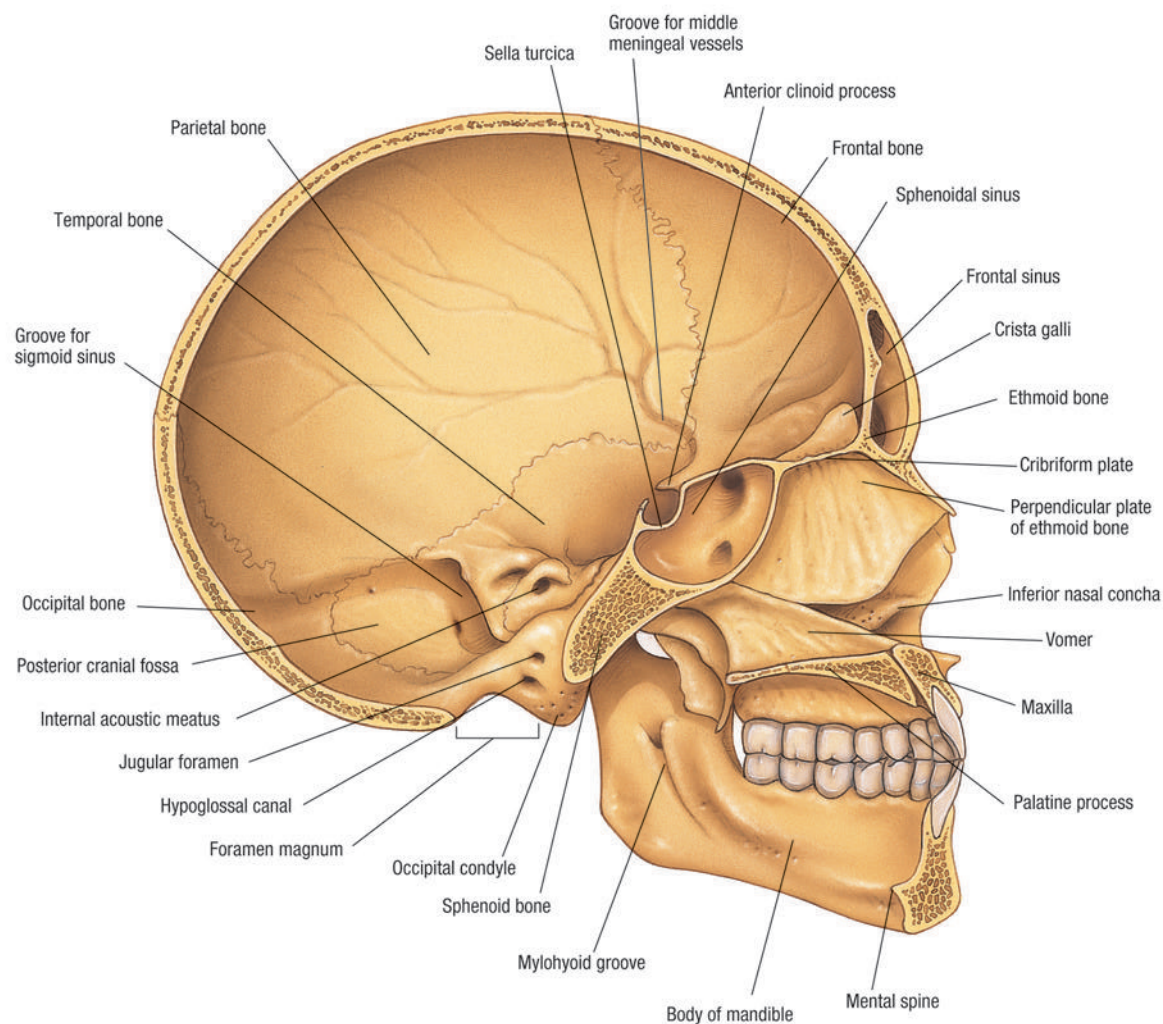


## PLATE 2: LATERAL VIEW OF SKULL



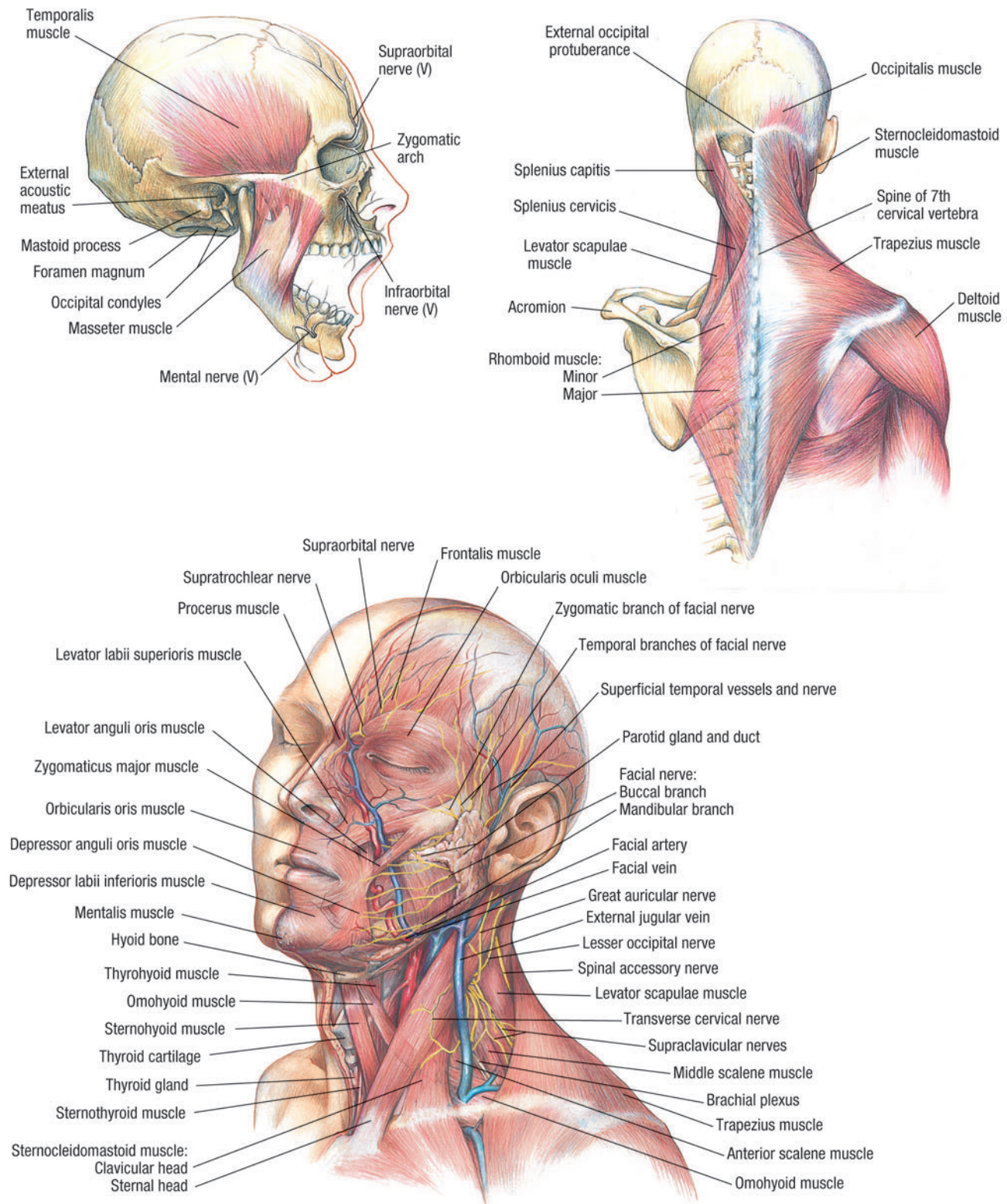
## PLATE 3: SAGITTAL SECTION THROUGH SKULL

**Sagittal Section through Skull**



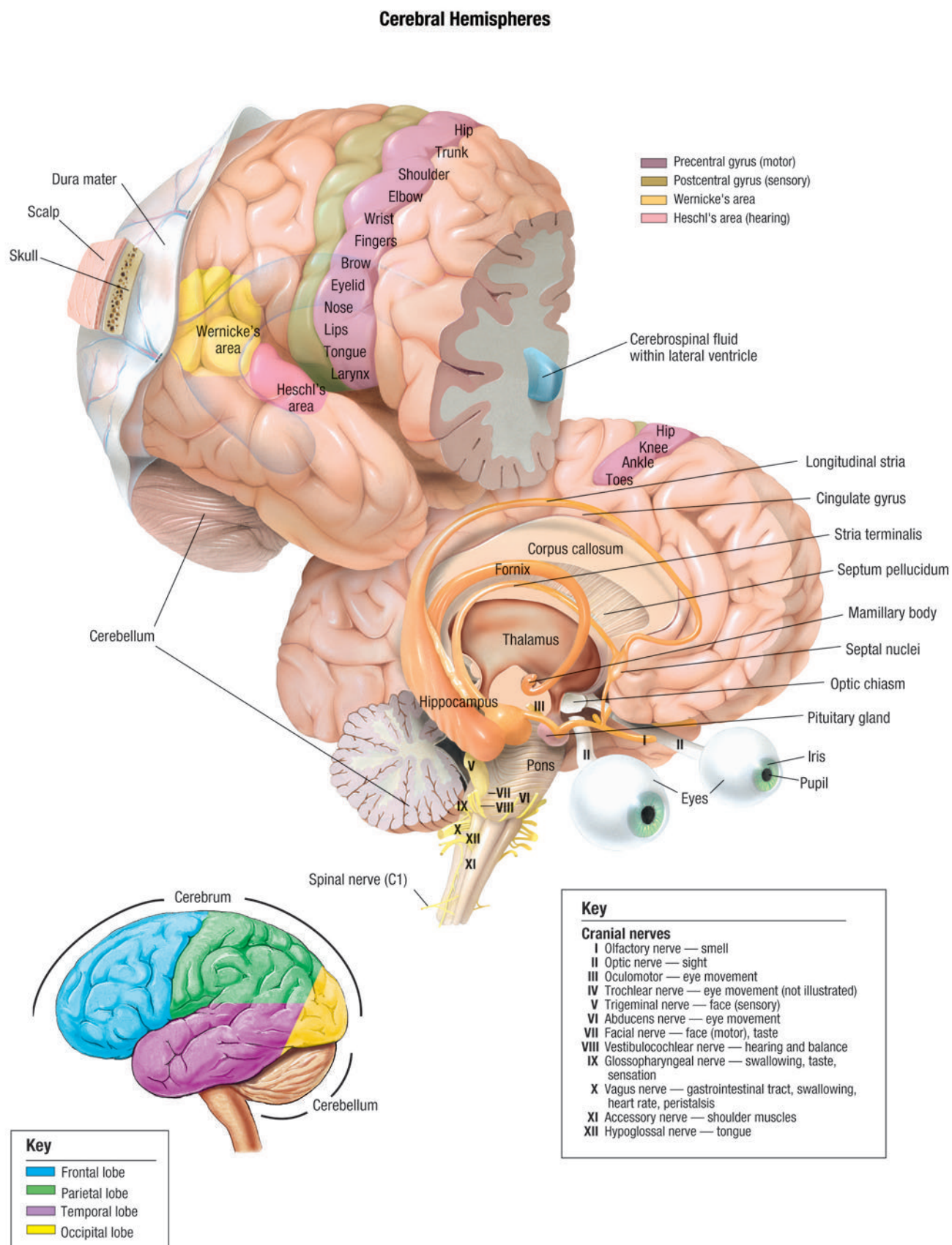
# PLATE 4: MUSCULAR ANATOMY OF HEAD AND NECK

## Muscular Anatomy of Head and Neck



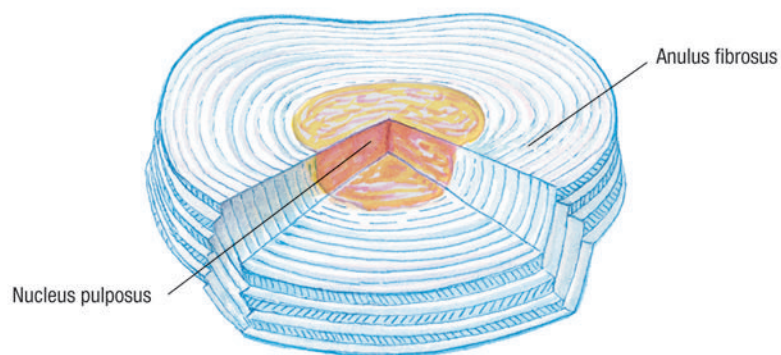
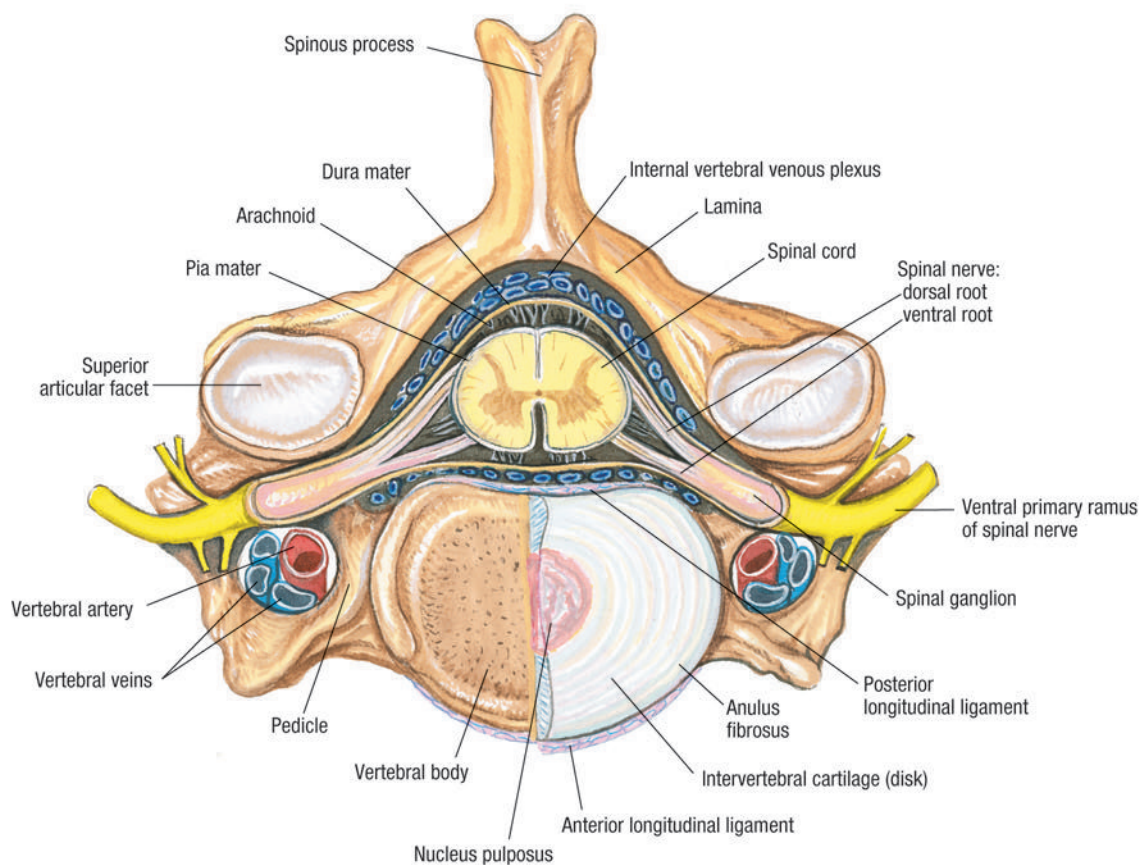


# PLATE 5: CEREBRAL HEMISPHERES



## PLATE 6: VERTEBRAL AND INTERVERTEBRAL DISK ANATOMY

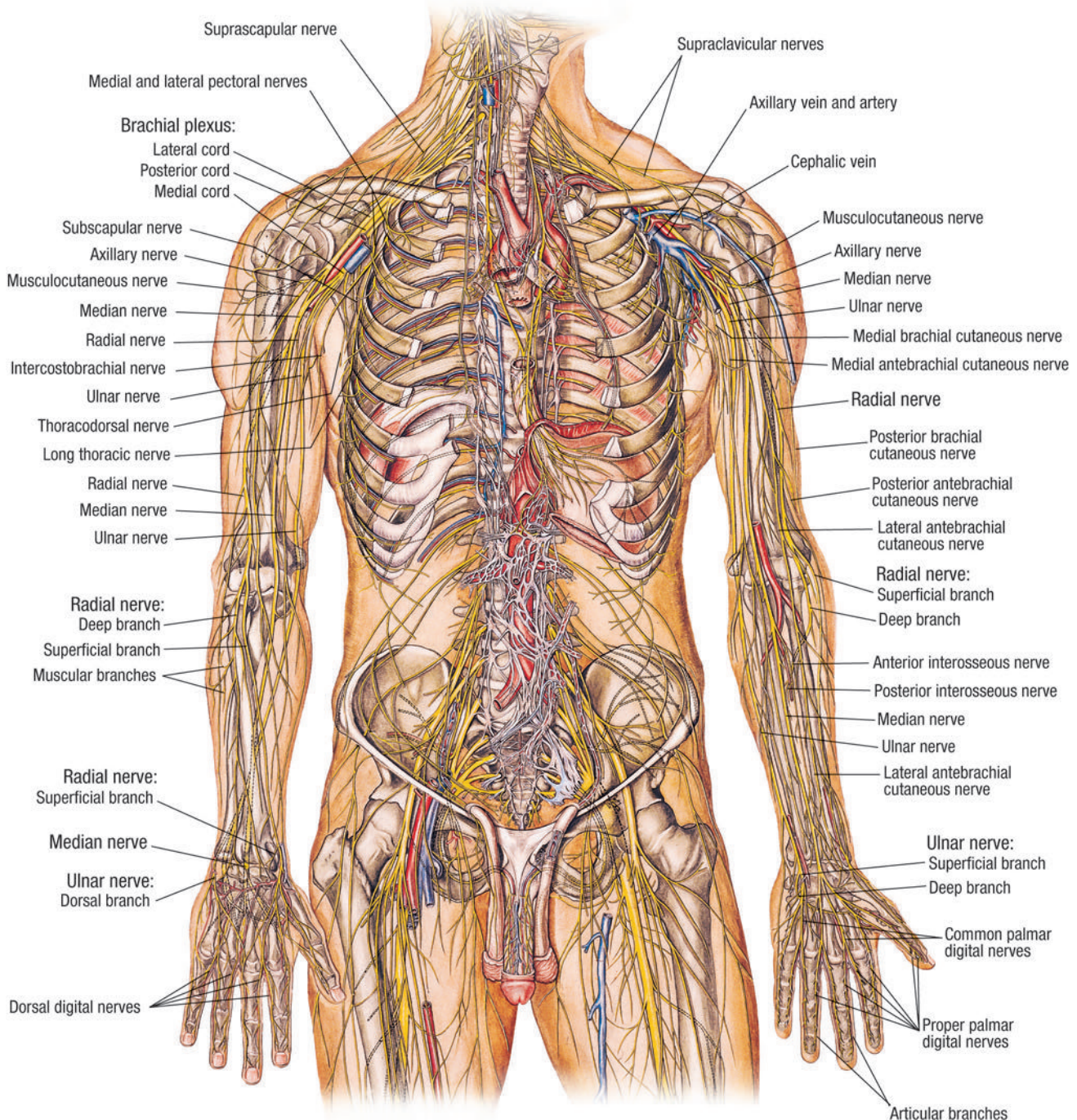
Vertebral and Intervertebral Disk Anatomy (Viewed from above)





## PLATE 7: NERVOUS SYSTEM OF THORAX AND UPPER LIMB (ANTERIOR VIEW)

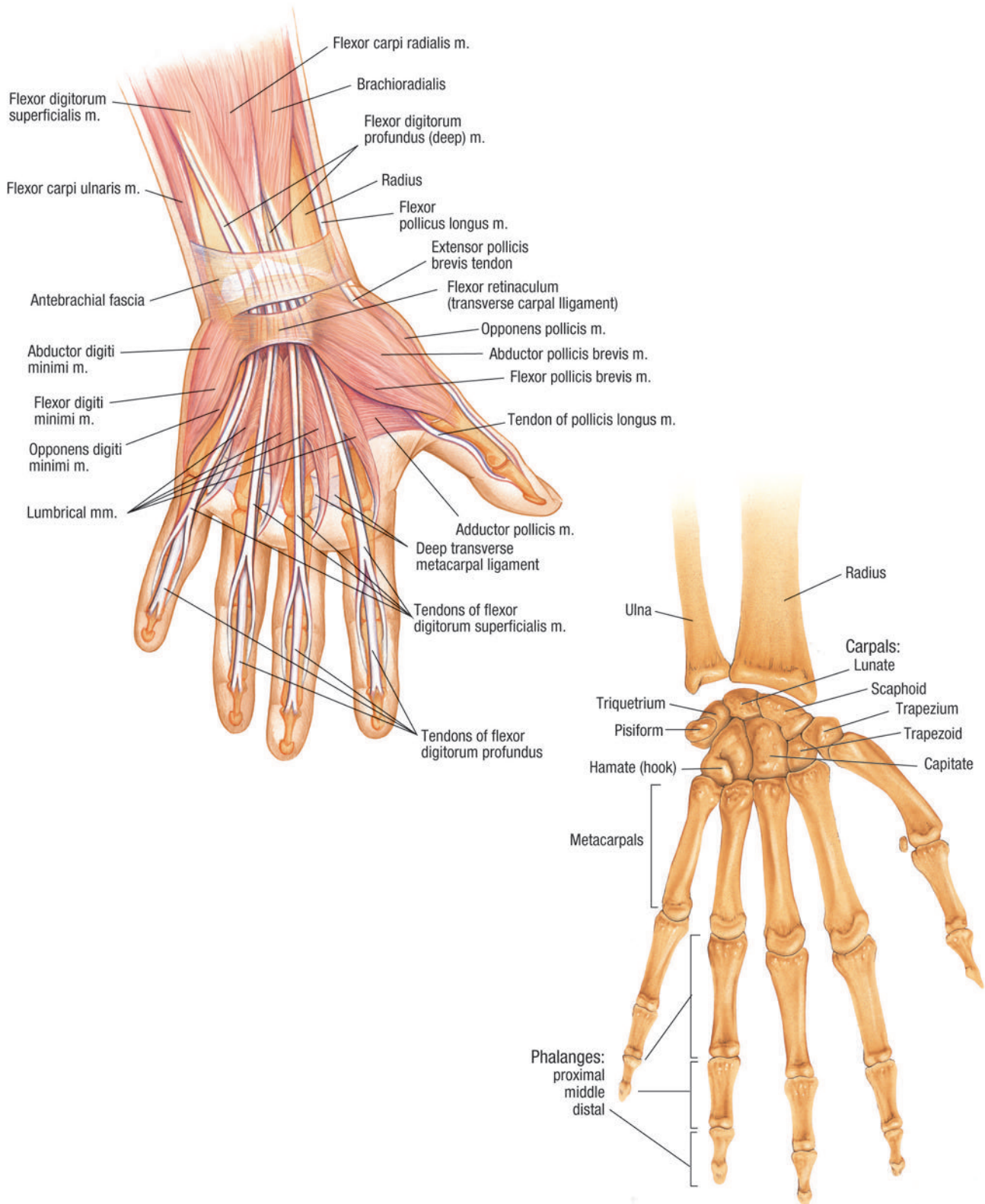
Nervous System of Thorax and Upper Limb (Anterior view)





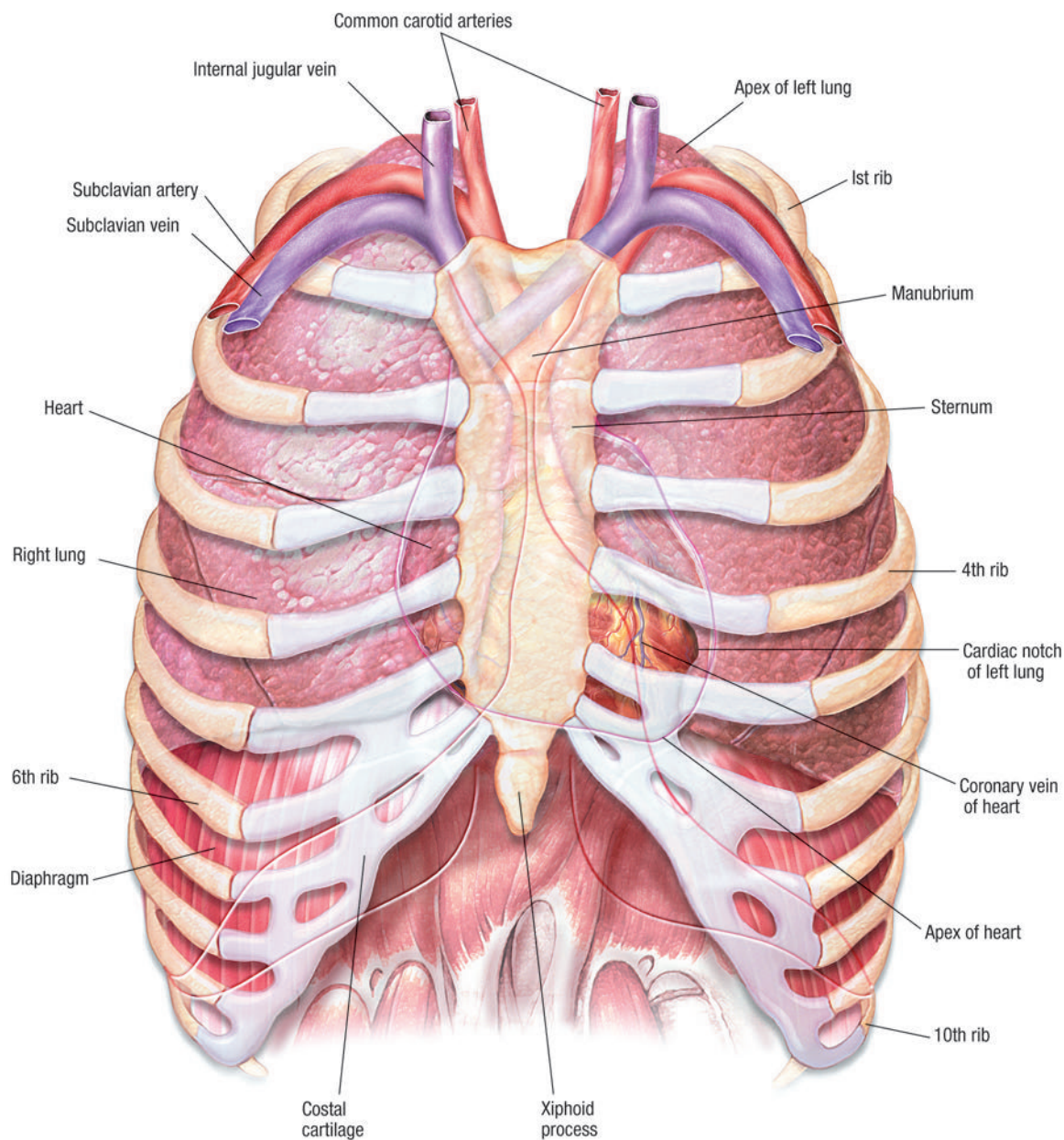
# PLATE 8: MUSCULAR AND SKELETAL ANATOMY OF WRIST AND HAND (PALMAR VIEW)

**Muscular and Skeletal Anatomy of Wrist and Hand (Palmar view)**



## PLATE 9: VISCERA OF THORAX (ANTERIOR VIEW)

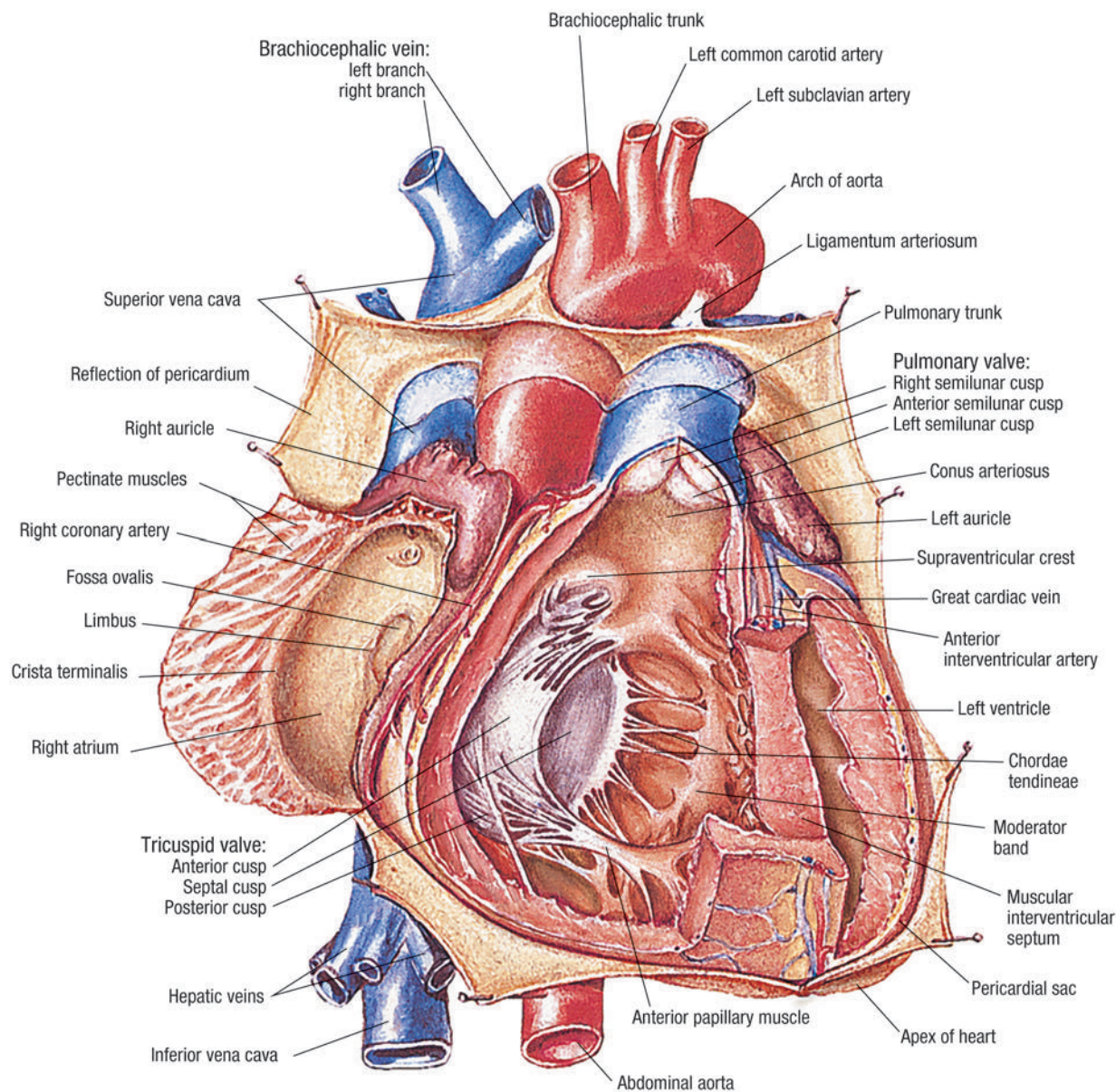
Viscera of Thorax (Anterior view)





## PLATE 10: ANATOMY OF THE HEART (ANTERIOR VIEW)

Anatomy of the Heart (Anterior view)



Return to:

◀ Image Gallery

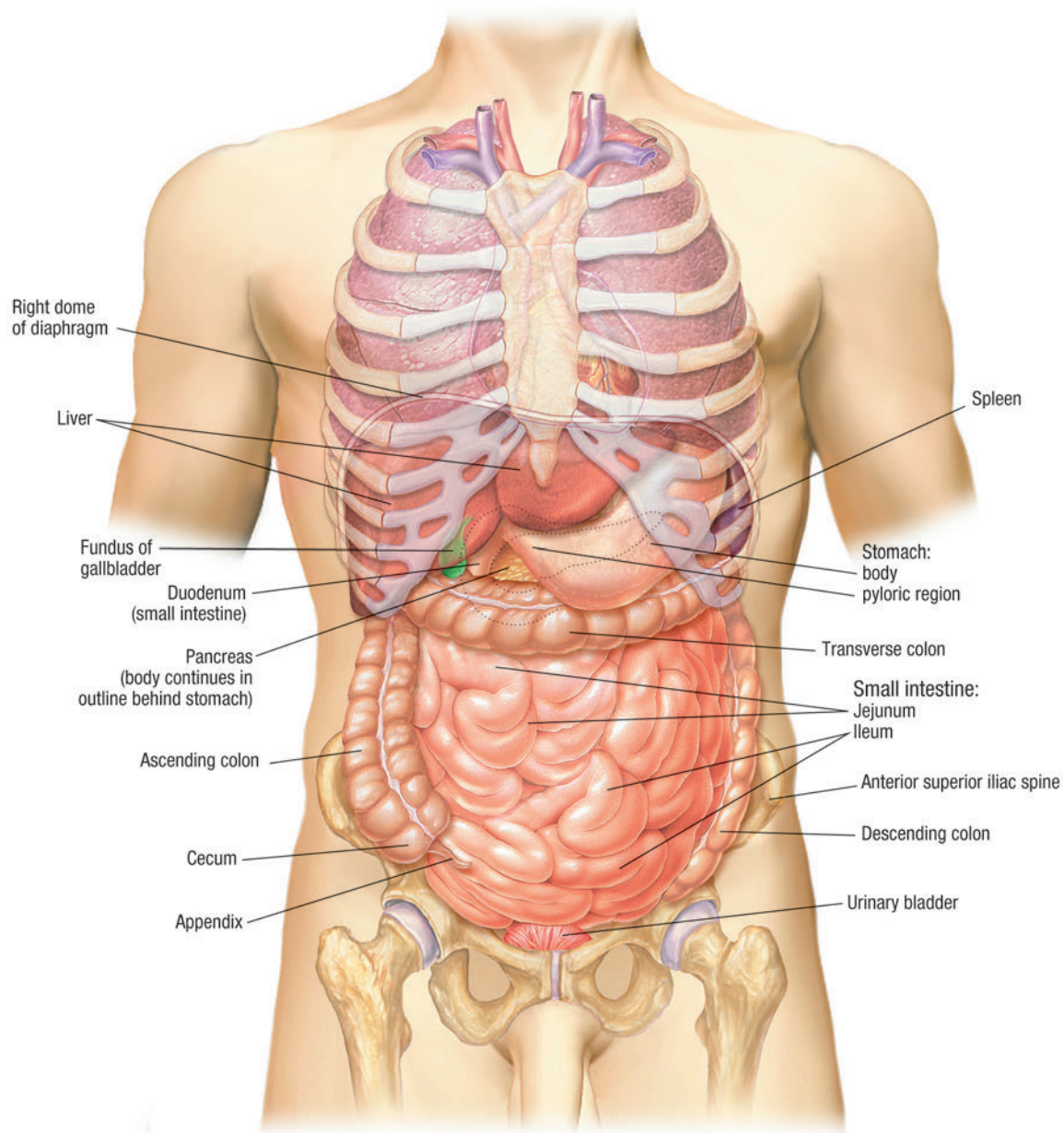
◀ Image List

To enlarge, click on image.

Click on image again to return to original size.

## PLATE 11: ABDOMINAL VISCERA (ANTERIOR VIEW)

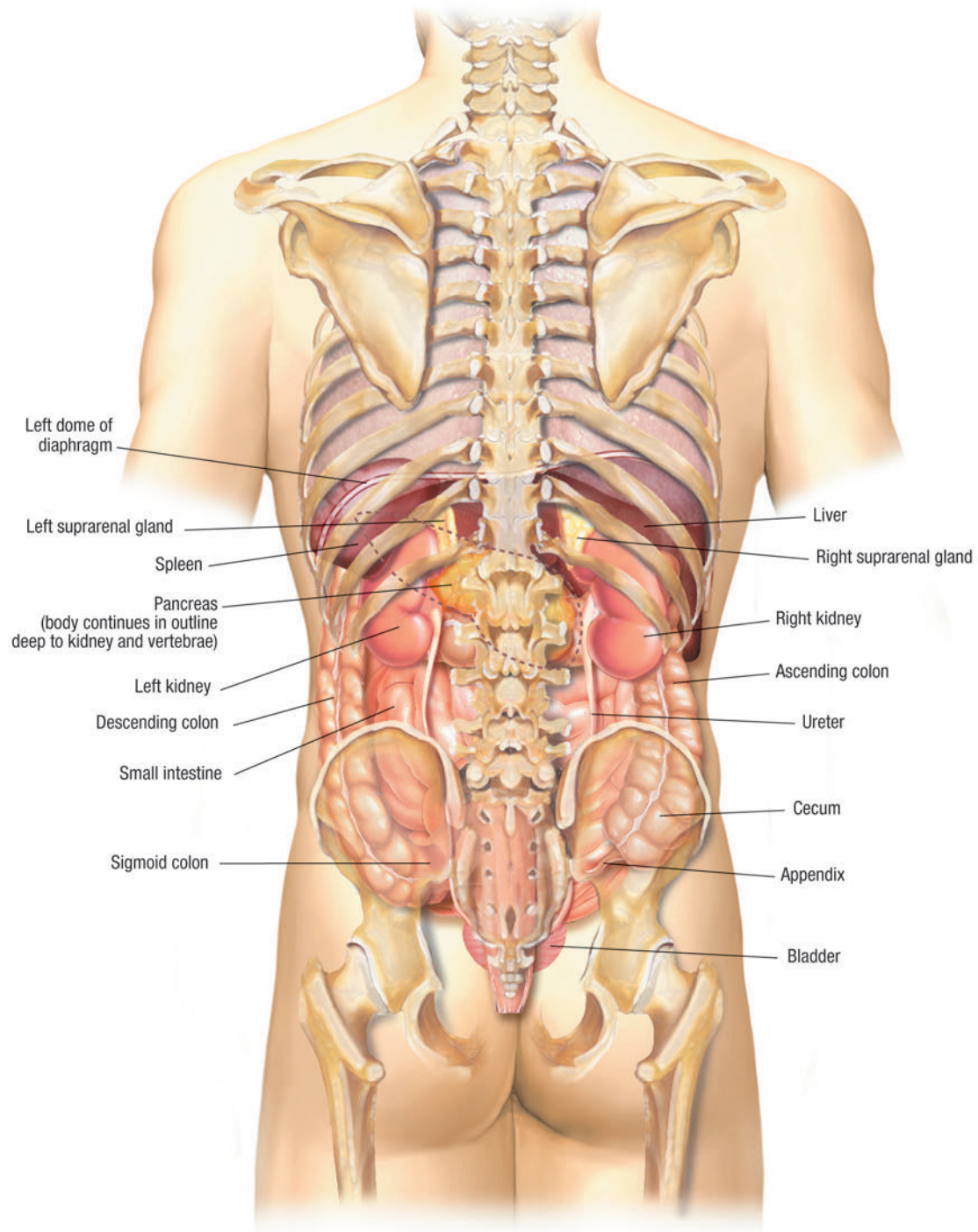
**Abdominal Viscera (Anterior view)**





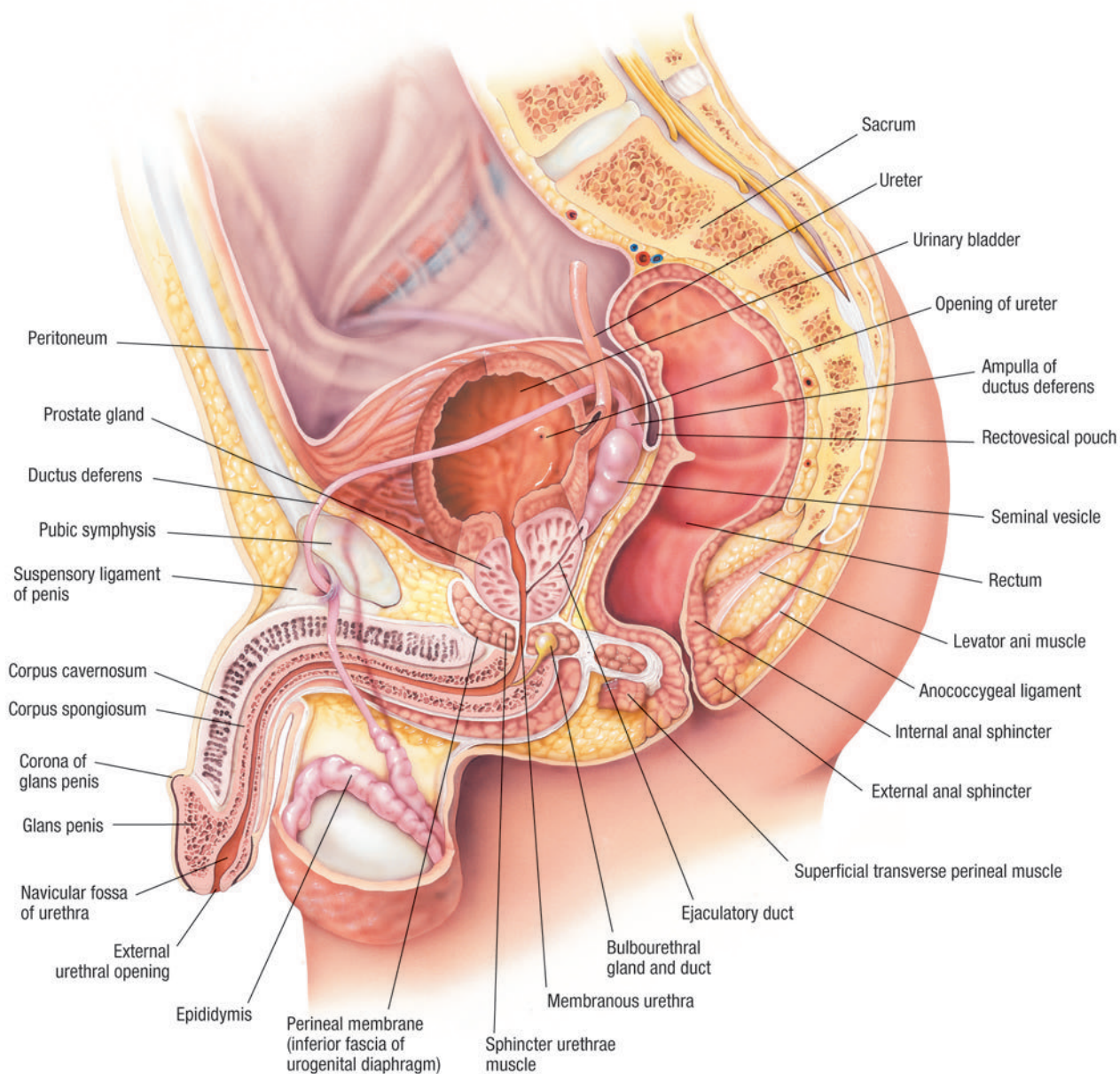
## PLATE 12: ABDOMINAL VISCERA (POSTERIOR VIEW)

Abdominal Viscera (Posterior view)



## PLATE 13: MALE UROGENITAL SYSTEM (MIDSAGITTAL VIEW)

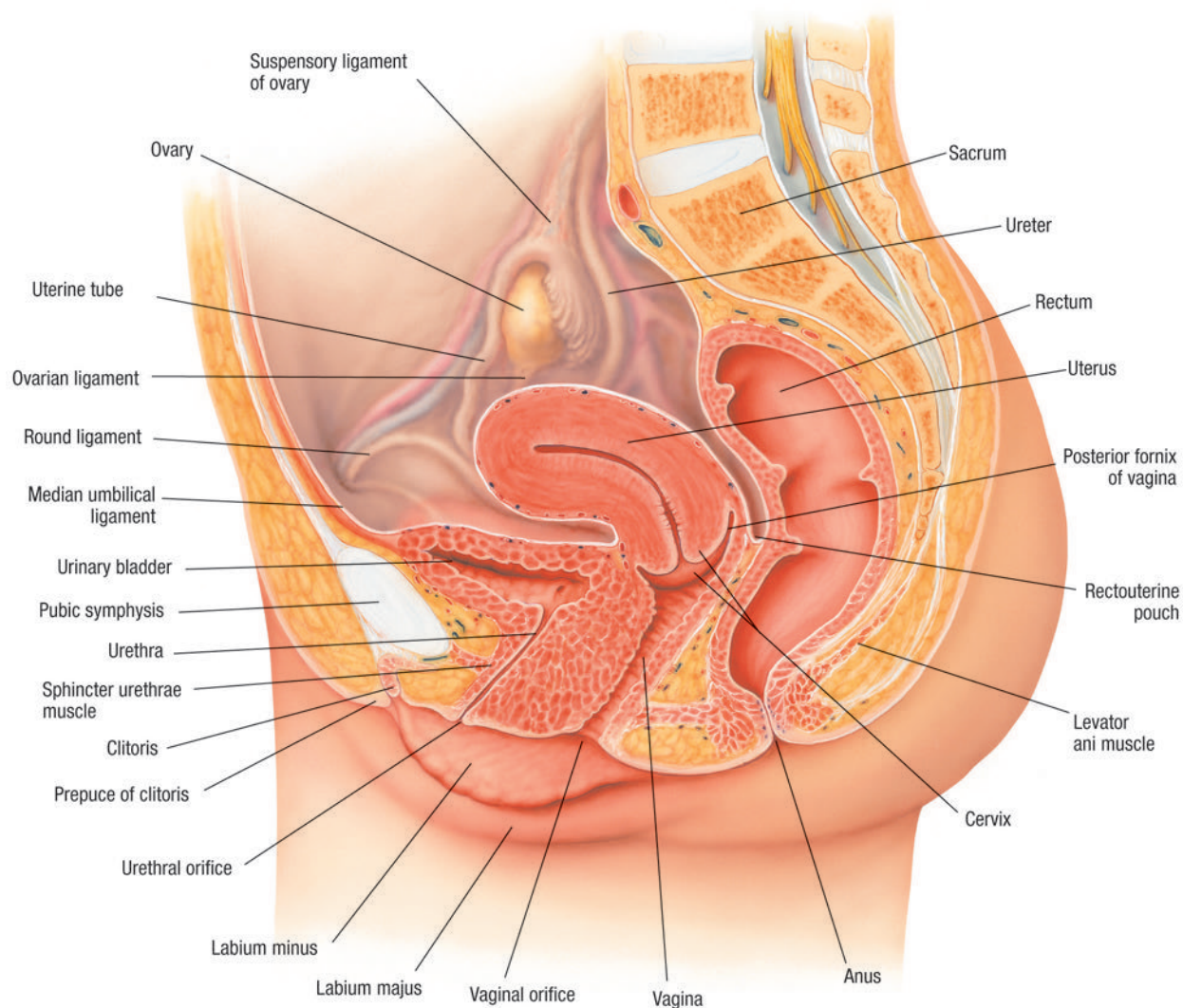
Male Urogenital System (Midsagittal view)





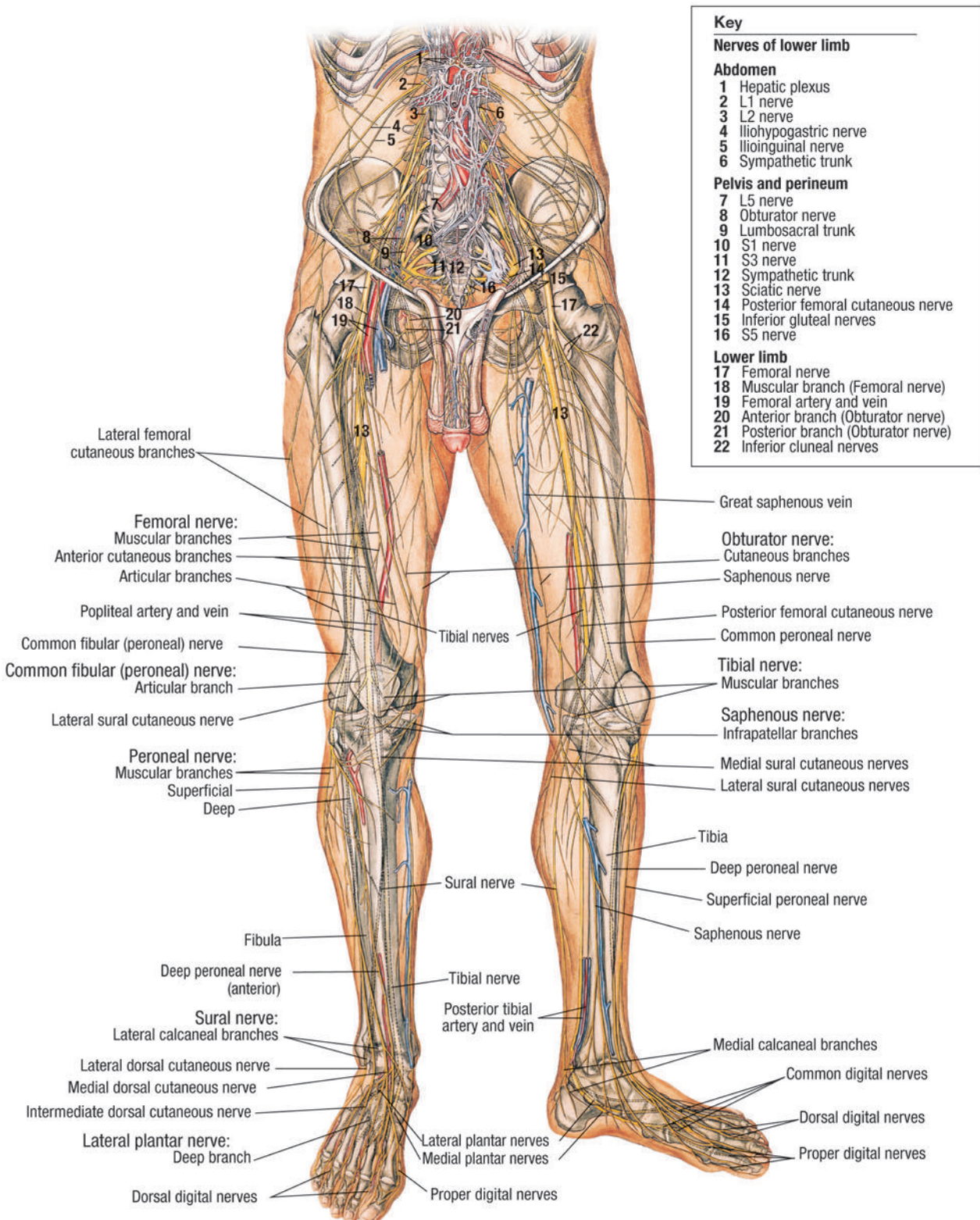
## PLATE 14: FEMALE UROGENITAL SYSTEM (MIDSAGITTAL VIEW)

Female Urogenital System (Midsagittal view)



# PLATE 15: NERVOUS SYSTEM OF PELVIS AND LOWER LIMB (ANTERIOR VIEW)

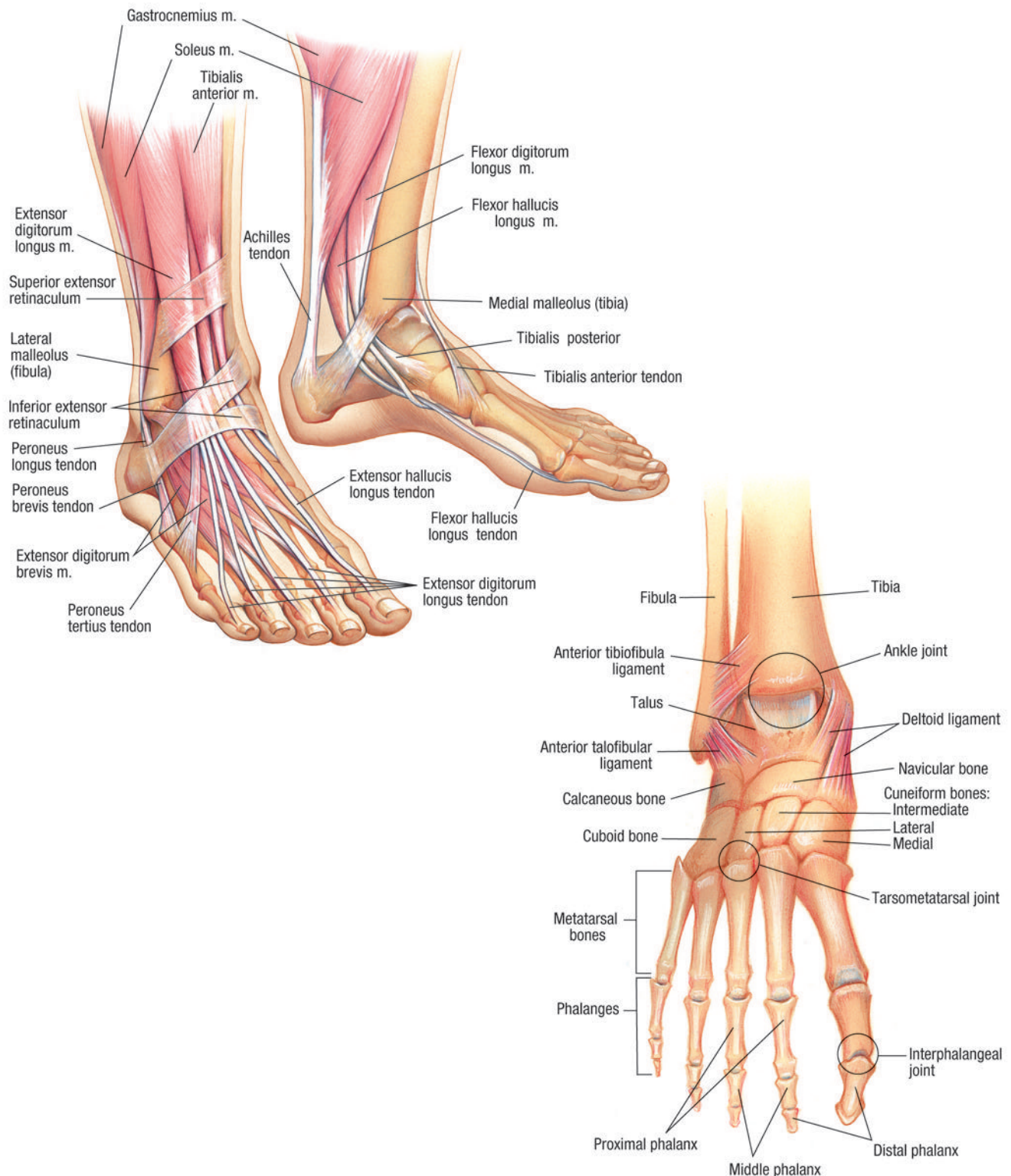
Nervous System of Pelvis and Lower Limb (Anterior view)



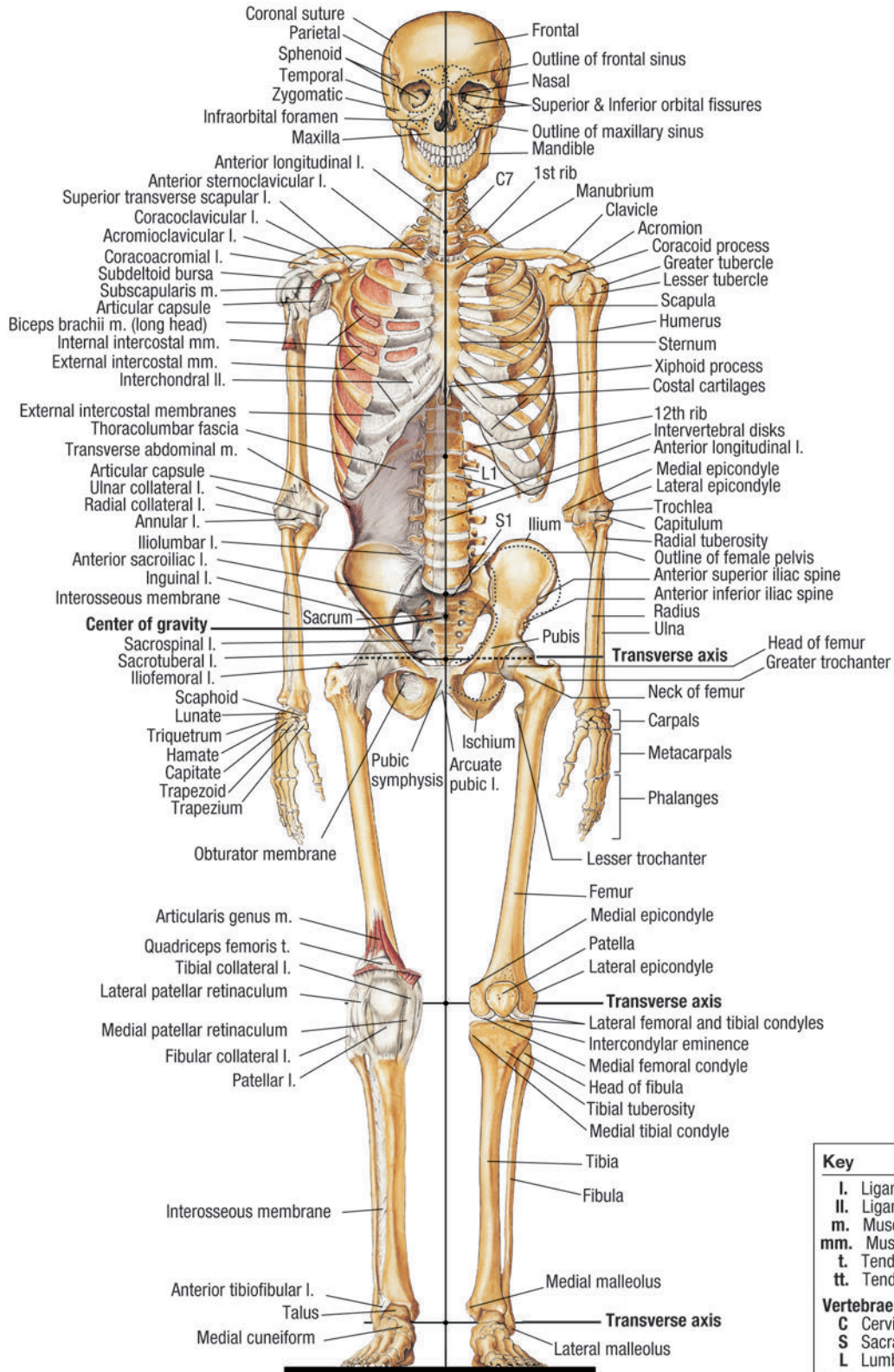


# PLATE 16: MUSCULAR AND SKELETAL ANATOMY OF ANKLE AND FOOT (ANTERIOR VIEW)

**Muscular and Skeletal Anatomy of Ankle and Foot (Anterior view)**



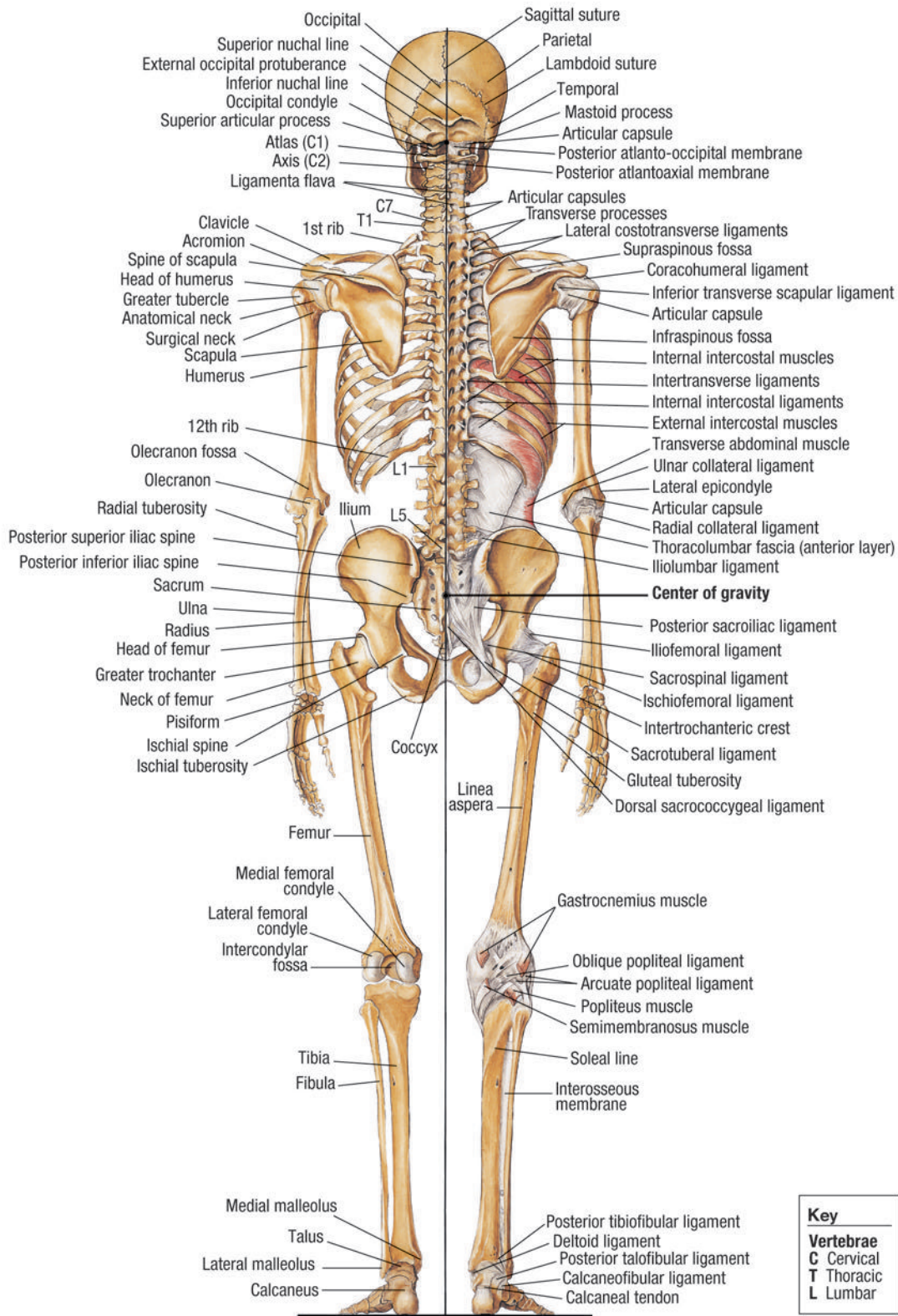
### Skeletal Anatomy (Anterior view)





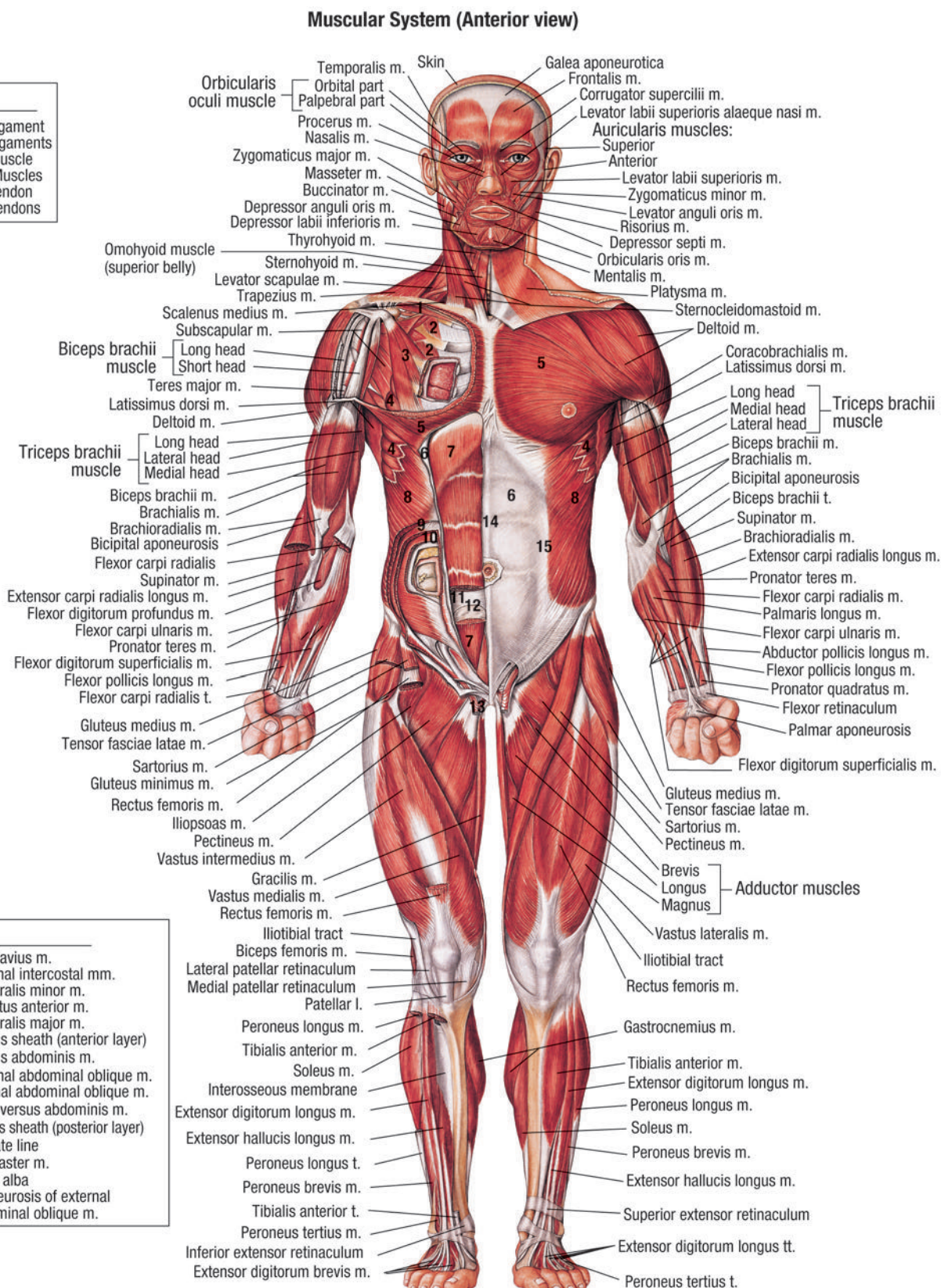
# PLATE 18: SKELETAL ANATOMY (POSTERIOR VIEW)

**Skeletal Anatomy (Posterior view)**



# PLATE 19: MUSCULAR SYSTEM (ANTERIOR VIEW)

Key	
I.	Ligament
II.	Ligaments
m.	Muscle
mm.	Muscles
t.	Tendon
tt.	Tendons

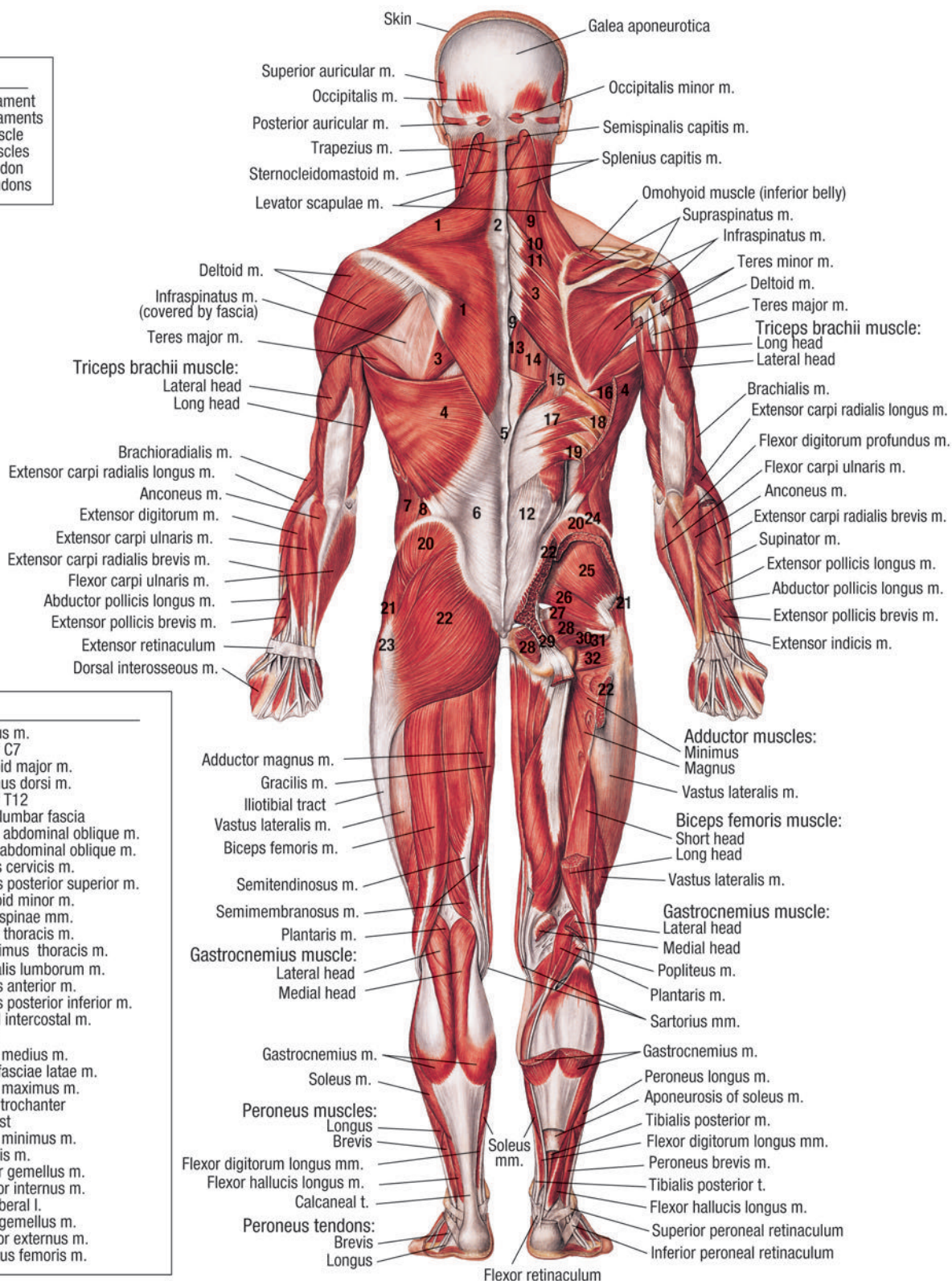




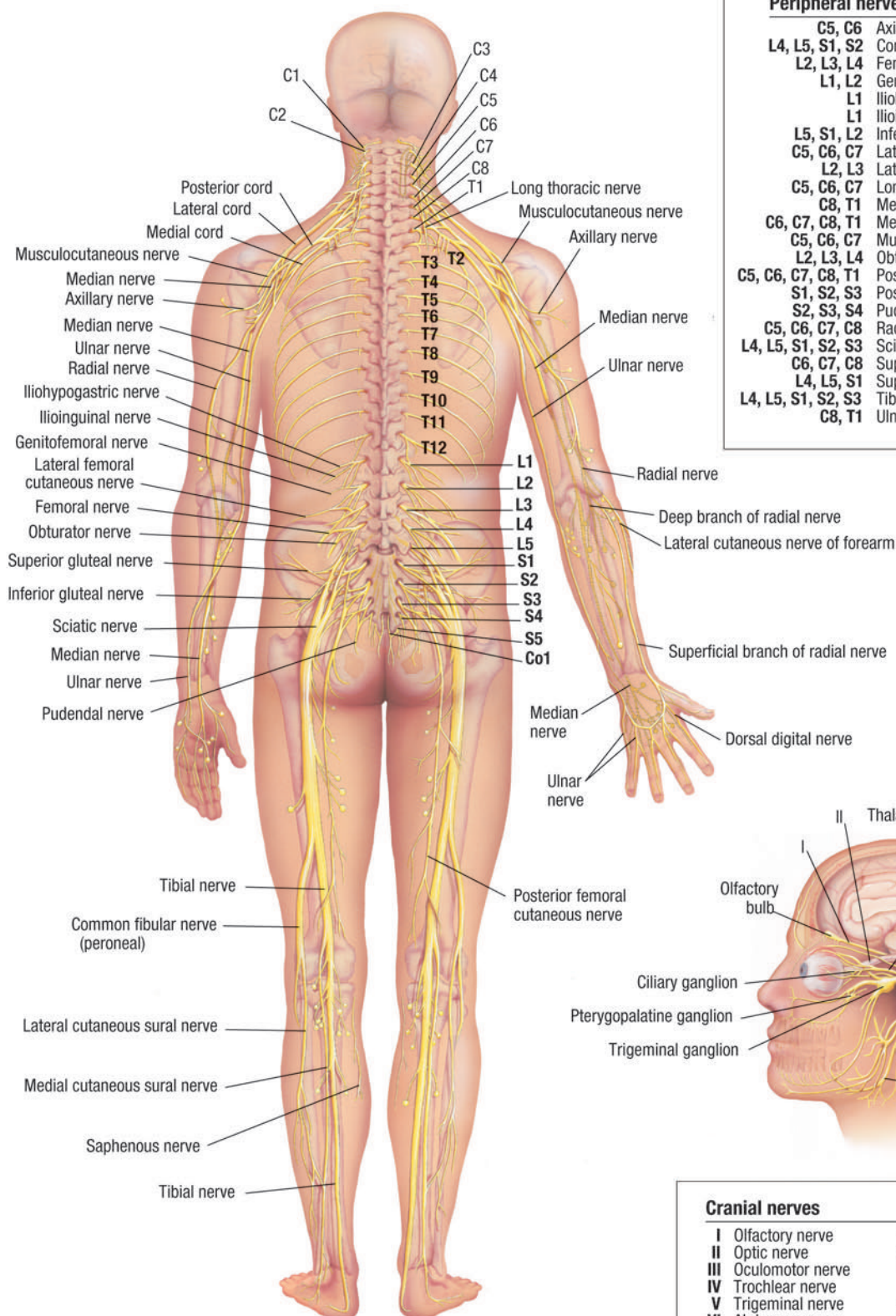
# PLATE 20: MUSCULAR SYSTEM (POSTERIOR VIEW)

## Muscular System (Posterior view)

Key	
I.	Ligament
II.	Ligaments
m.	Muscle
mm.	Muscles
t.	Tendon
tt.	Tendons

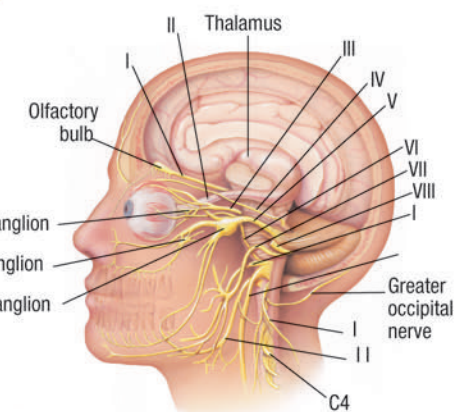


## Spinal and Cranial Nerves



### Peripheral nerve origins

C5, C6	Axillary nerve
L4, L5, S1, S2	Common fibular (peroneal) nerve
L2, L3, L4	Femoral nerve
L1, L2	Genitofemoral nerve
L1	Iliohypogastric nerve
L1	Ilioinguinal nerve
L5, S1, L2	Inferior gluteal nerve
C5, C6, C7	Lateral cord
L2, L3	Lateral femoral cutaneous nerve
C5, C6, C7	Long thoracic nerve
C8, T1	Medial cord
C6, C7, C8, T1	Median nerve
C5, C6, C7	Musculocutaneous nerve
L2, L3, L4	Obturator nerve
C5, C6, C7, C8, T1	Posterior cord
S1, S2, S3	Posterior femoral cutaneous nerve
S2, S3, S4	Pudendal nerve
C5, C6, C7, C8	Radial nerve
L4, L5, S1, S2, S3	Sciatic nerve
C6, C7, C8	Superficial branch of radial nerve
L4, L5, S1	Superior gluteal nerve
L4, L5, S1, S2, S3	Tibial nerve
C8, T1	Ulnar nerve



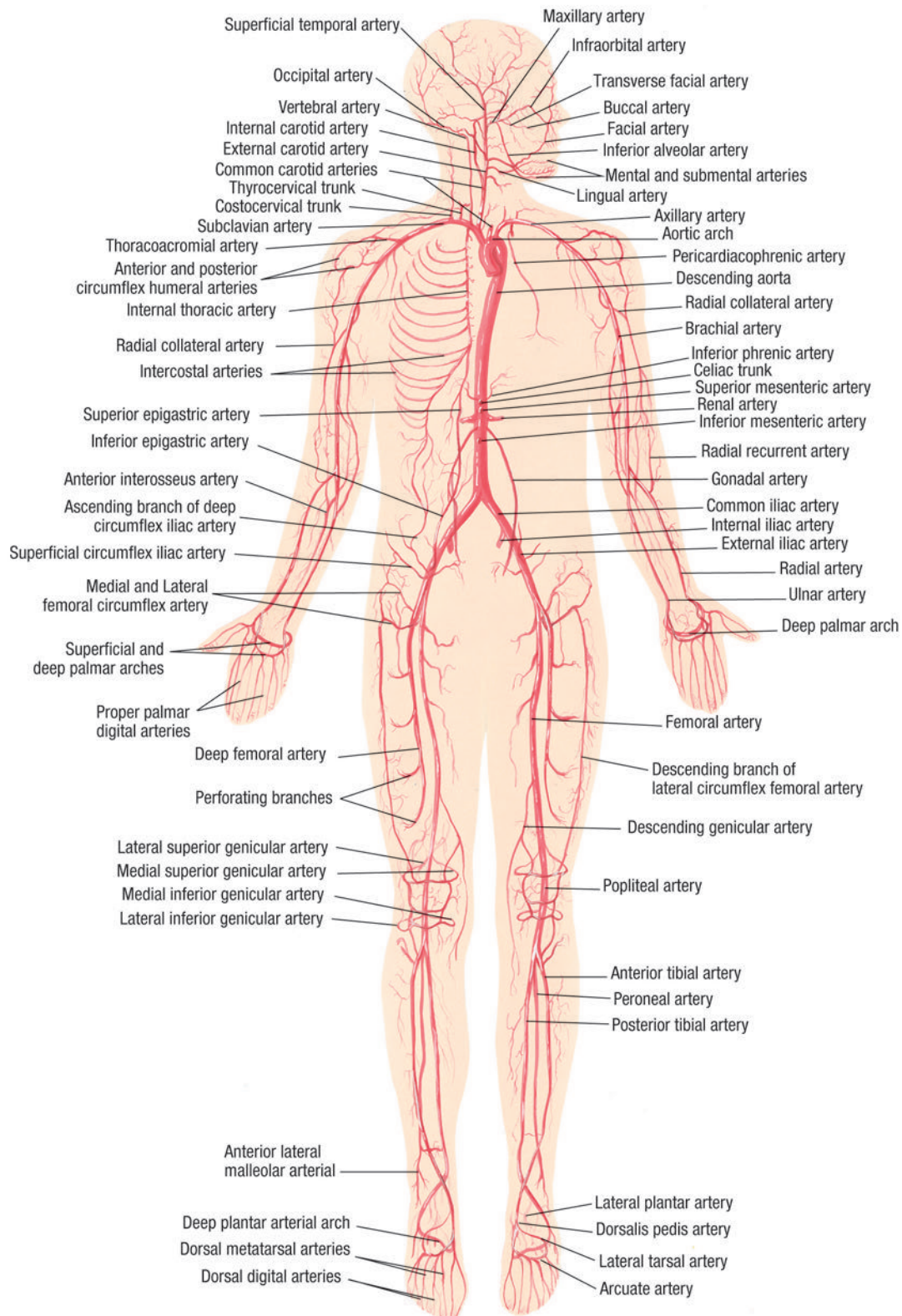
### Cranial nerves

I	Olfactory nerve	VI	Facial nerve
II	Optic nerve	VIII	Vestibulocochlear nerve
III	Oculomotor nerve	IX	Glossopharyngeal nerve
IV	Trochlear nerve	X	Vagus nerve
V	Trigeminal nerve	XI	Accessory nerve
VI	Abducens nerve	XII	ypoglossal nerve



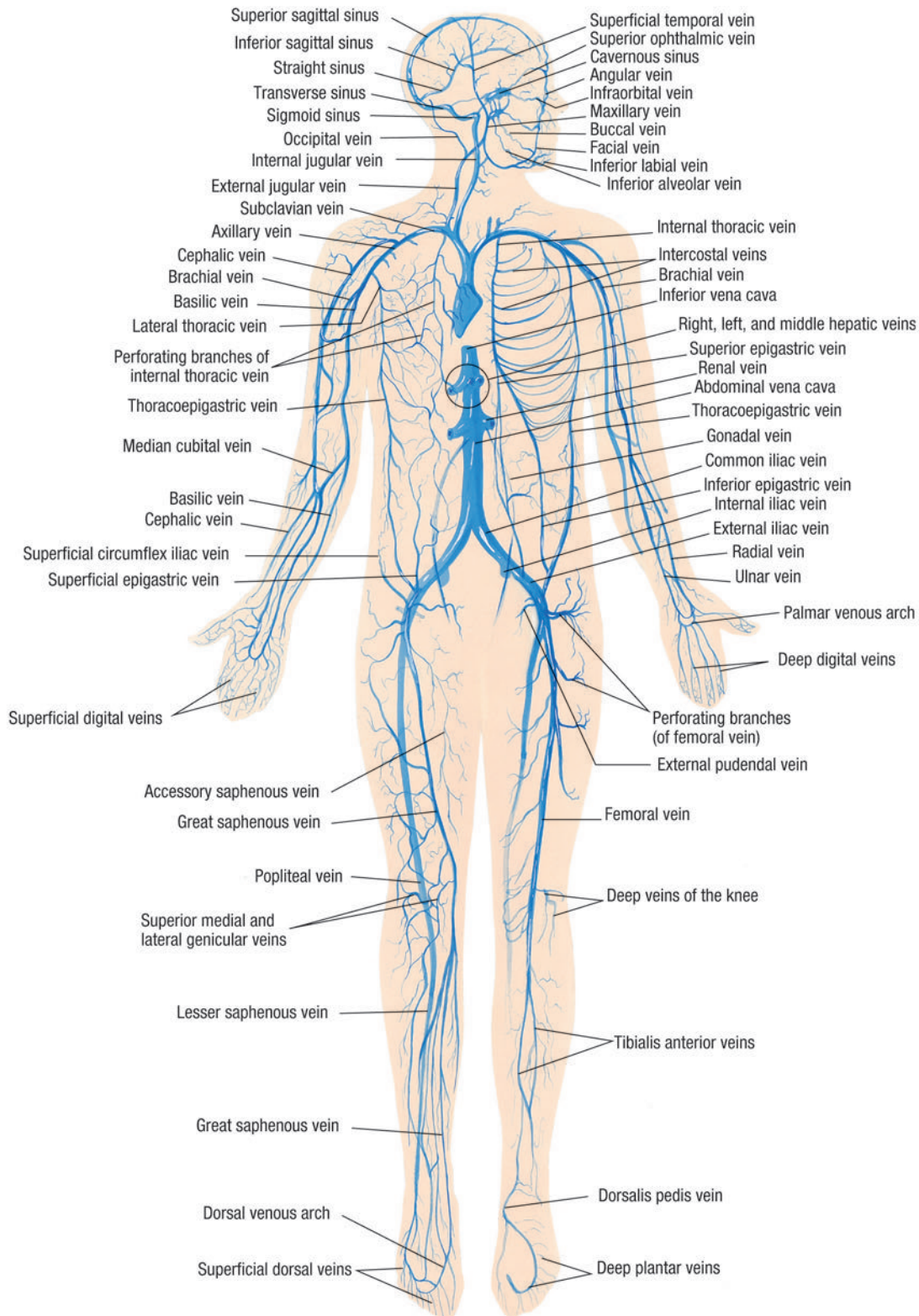
## PLATE 22: ARTERIAL SYSTEM (ANTERIOR VIEW)

**Arterial System (Anterior view)**



## PLATE 23: VENOUS SYSTEM (ANTERIOR VIEW)

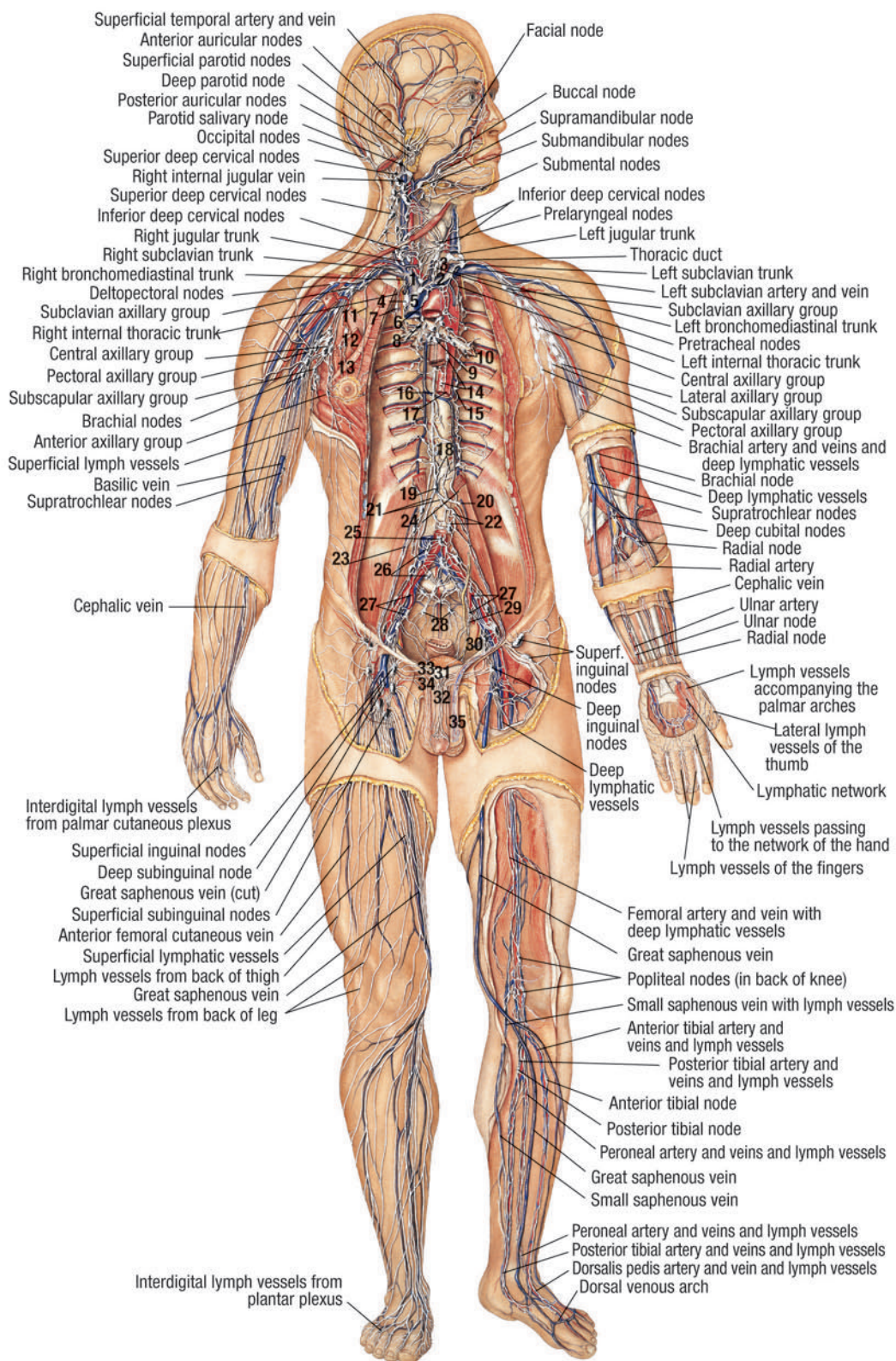
**Venous System (Anterior view)**





# PLATE 24: LYMPHATIC SYSTEM (ANTERIOR VIEW)

**Lymphatic System (Anterior view)**



## Key

- 1 Right brachiocephalic vein
- 2 Left brachiocephalic vein
- 3 Left common carotid artery
- 4 Anterior superior mediastinal nodes
- 5 Superior vena cava
- 6 Right cardiac lymph branch
- 7 Internal thoracic node
- 8 Right tracheobronchial nodes
- 9 Left tracheobronchial nodes
- 10 Right and left bronchopulmonary nodes
- 11 Internal thoracic lymph vessel ending in subclavicular nodes
- 12 Interpectoral nodes
- 13 Lymph vessels from deep part of breast
- 14 Posterior mediastinal nodes
- 15 Intercostal nodes and lymph vessels
- 16 Thoracic duct
- 17 Thoracic aorta
- 18 Descending right and left intercostal lymph trunks
- 19 Cisterna chyli
- 20 Intestinal trunk
- 21 Right and left lumbar trunks
- 22 Lumbar nodes
- 23 Testicular lymph vessels
- 24 Retroaortic node (lumbar nodes)
- 25 Preaortic node (lumbar nodes)
- 26 Common iliac nodes
- 27 Internal iliac artery and nodes
- 28 Sacral nodes
- 29 Lymph vessels to internal iliac nodes
- 30 Obturator vessels and nerve
- 31 Presymphysal node
- 32 Collecting lymph vessels from glans penis
- 33 Superficial lymph vessels from the penis
- 34 Lymph vessels from the scrotum
- 35 Lymph vessels of testis and epididymus

Return to:

Image Gallery

Image List

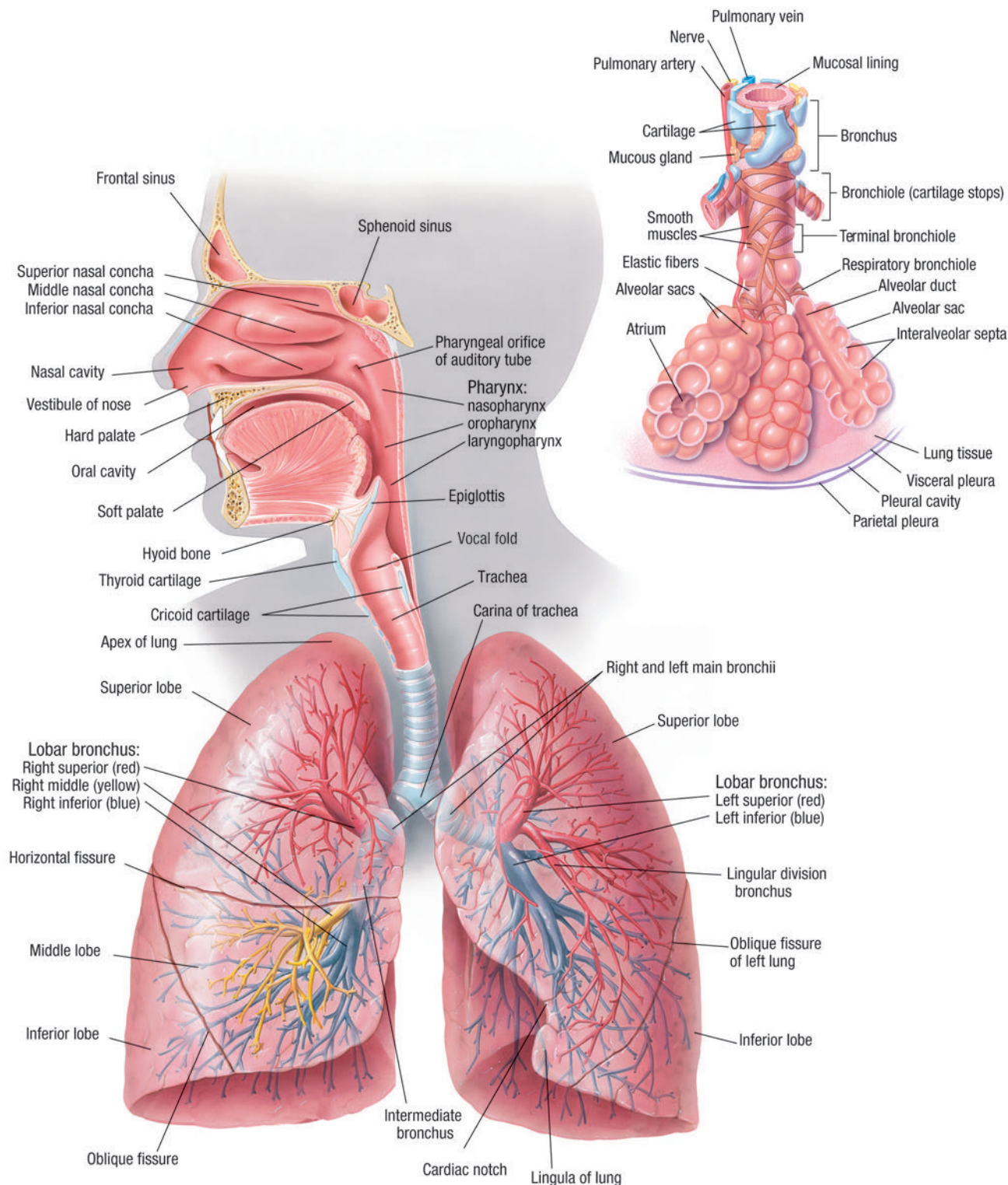
To enlarge, click on image.

Click on image again to return to original size.



# PLATE 25: RESPIRATORY SYSTEM (ANTERIOR VIEW)

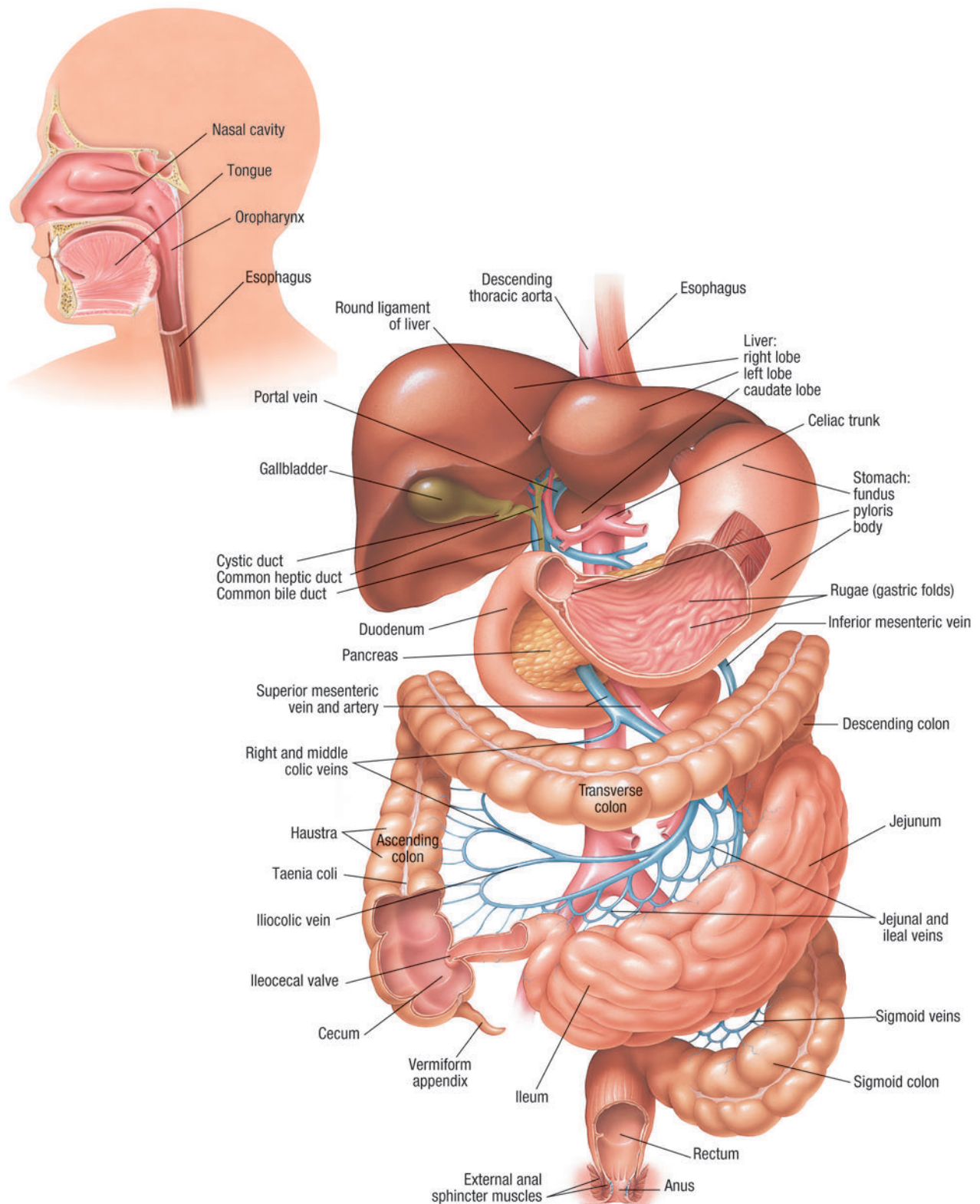
**Respiratory System (Anterior view)**





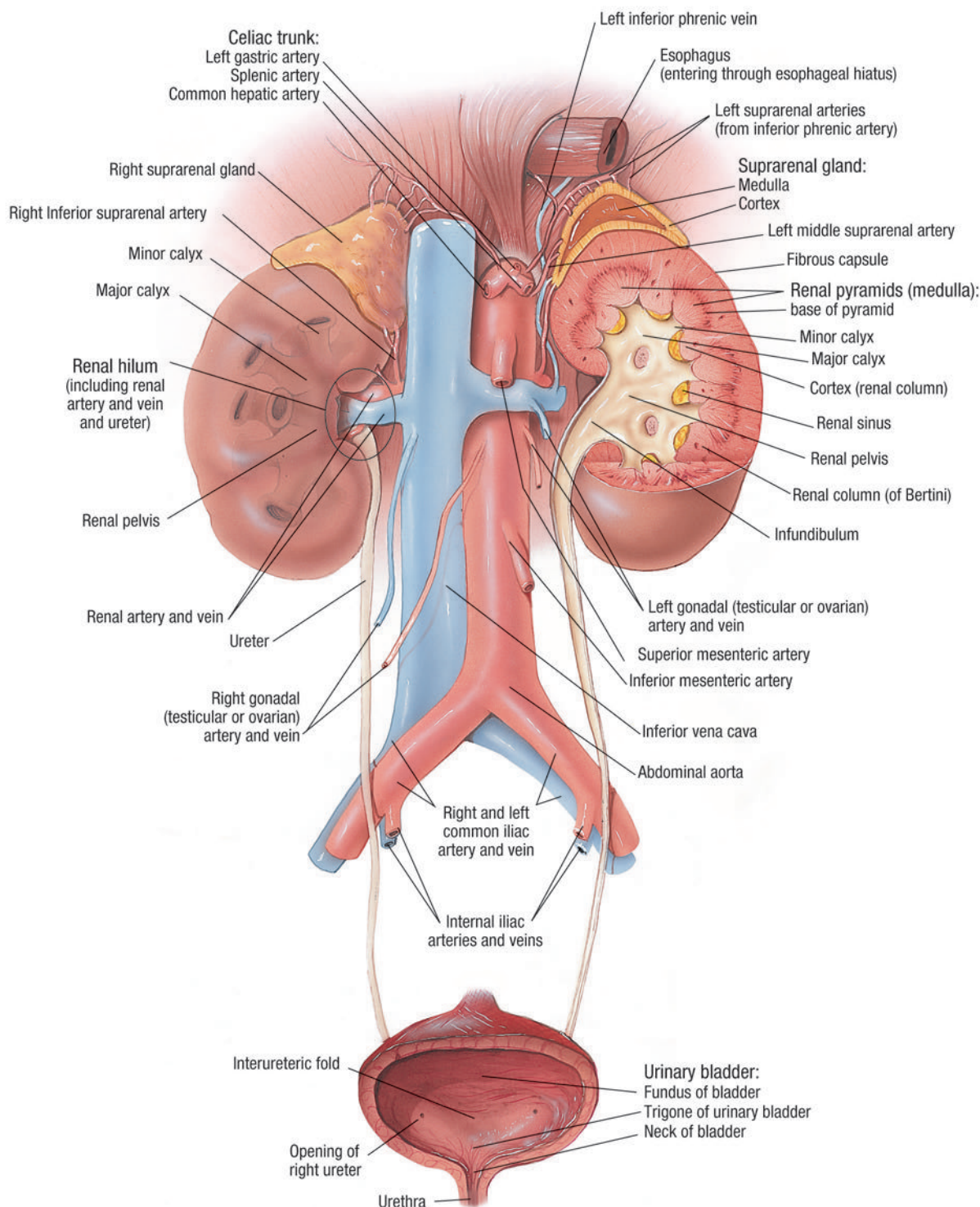
## PLATE 26: DIGESTIVE SYSTEM (ANTERIOR VIEW)

Digestive System (Anterior view)



## PLATE 27: URINARY SYSTEM (ANTERIOR VIEW)

Urinary System (Anterior view)



## To navigate from the screen:

- Click on labeled arrows or buttons.
- Click on linked type to go to linked page. Which type is linked will be explained on each page.

- If cursor changes to:



Click to start reading



Click to continue



Shift-click to read backwards



Click to exit



RETURN TO  
THUMBNAIL IMAGES



RETURN TO  
IMAGE TITLES